

Photodynamic Therapy Using Verteporfin for Choroidal Neovascularization in Angioid Streaks

SAAD SHAIKH, MD, ALAN J. RUBY, MD, AND GEORGE A. WILLIAMS, MD

• **PURPOSE:** To evaluate the efficacy of photodynamic therapy with verteporfin in the management of choroidal neovascularization (CNV) associated with angioid streaks.

• **DESIGN:** Retrospective case series.

• **METHODS:** Eleven eyes of nine patients with subfoveal or juxtafoveal CNV due to angioid streaks underwent visual acuity testing, ophthalmic examination, color photography, and fluorescein angiography to evaluate the results of photodynamic therapy with verteporfin. Retreatment of persistent CNV was based on criteria from the Treatment of Age-Related Macular Degeneration with Photodynamic Therapy Investigation (TAP) except in one case. Follow-up ranged from 5 to 28 months (mean, 17 months).

• **RESULTS:** Nine of 11 eyes had subfoveal lesions while two eyes had juxtafoveal lesions on initial examination. Conversion from a choroidal neovascular membrane (CNVM) to a fibrous disciform lesion following photodynamic therapy was observed in nine eyes. Enlargement of the CNVM was noted in seven of these eyes by fluorescein angiography at final follow-up. Initial best-corrected visual acuity (BCVA) ranged from 20/25 to counting fingers (CF) (mean, 20/400; median, 20/200). Final BCVA ranged from 20/20 to CF (mean, 20/600; median, 20/400). Seven eyes with subfoveal CNVM had an initial BCVA of at least 20/200 while only three eyes maintained this level or better at last follow-up. In one patient with a juxtafoveal CNVM in one eye, vision decreased from 20/25 to 20/400 with enlargement and fibrosis of the CNVM and subfoveal extension. In the

fellow eye a juxtafoveal CNVM was initially treated and then retreated earlier than TAP criteria at 6 weeks. Vision improved to 20/20 and has remained stable 5 months after the initial treatment.

• **CONCLUSIONS:** Verteporfin for choroidal neovascularization-associated with angioid streaks does not appear to significantly alter the course of this disease with most eyes undergoing enlargement and disciform transformation of the neovascular process. However, aggressive management of these patients with biomicroscopic and fluorescein angiographic examination and timely photodynamic therapy with early retreatment when indicated may be beneficial in certain cases. (Am J Ophthalmol 2003;135:1-6. © 2003 by Elsevier Science Inc. All rights reserved.)

ANGIOID STREAKS REPRESENT DEHISCENCES IN Bruch's membrane and are associated with various systemic diseases such as pseudoxanthoma elasticum, Ehlers-Danlos syndrome, Paget disease, and various blood dyscrasias.¹ Choroidal neovascularization (CNV) has been reported to occur in 72% to 86% of patients with angioid streaks.²⁻⁴ The natural history of such lesions is poor, with most resulting in macular involvement and central visual loss.⁵ Most patients become legally blind by the age of 50.⁶ Although conventional laser photocoagulation for juxtafoveal and extrafoveal choroidal neovascularization secondary to angioid streaks may mitigate the rate of visual loss,⁷ treatment modalities for subfoveal neovascularization remain limited. Macular translocation has been described in two cases with limited follow-up.⁸

Recently, photodynamic therapy with verteporfin has been introduced as a treatment for reducing visual loss in patients with CNV due to age-related macular degeneration, pathologic myopia, and presumed ocular histoplasmosis syndrome.⁹⁻¹² Although results of photodynamic therapy for a single patient with subfoveal choroidal neovascularization from angioid streaks were reported as part of the original phase 1 and 2 trial of photodynamic therapy for age-related macular degeneration, no reports in the literature describe the use of photodynamic therapy

Accepted for publication Aug 16, 2002.

From the Associated Retinal Consultants and The Beaumont Eye Institute, Royal Oak, Michigan.

Presented in part at the Association for Research and Vision in Ophthalmology Annual Meeting 2002 Fort Lauderdale, Florida and at the Joint Retina and Vitreous Annual Society Meeting 2002 in San Francisco, California.

Saad Shaikh, MD, is a Heed Foundation and Michels Foundation Fellow.

Inquiries to Alan J. Ruby, MD, Associated Retinal Consultants and The Beaumont Eye Institute, 632 William Beaumont Medical Building, 3535 West Thirteen Mile Road, Royal Oak, MI 48073.

TABLE 1. Clinical Characteristics of the Study Population

Case	Age/Sex/History	Eye	Duration	Lesion Size (microns)	Preop BCVA	Postop BCVA	Anatomic Outcome	Treatments (interval wks)	Follow up
1*	79 yo, M, Paget's	OD	11 m	2600	20/400	CF	larger, fibrous change	1	20 m
2*	79 yo, F	OS	4 m	2400	20/200	CF	larger, fibrous change	2 (16)	18 m
3*	65 yo, F, PXE	OD	60 m	4000	CF	20/400	stable	2 (14)	21 m
		OS	20 m	4000	CF	CF	larger, fibrous change	1	19 m
4	45 yo, F	OS	1 w	2400	CF	CF	larger, fibrous change	2 (15)	18 m
5†	54 yo, M, PXE	OS	1 w	2200	20/25	20/400	larger, fibrous change	3 (12, 8)	12 m
		OD	1 w	600	20/30	20/20	stable	2 (6)	5 m
6	63 yo, F	OS	1 m	800	20/200	20/400	fibrous change	4 (15, 16, 28)	15 m
7‡	44 yo, F, PXE	OS	37 m	2400	20/60	20/50	fibrous change	2 (12)	10 m
8*	45 yo, F, PXE	OD	11 m	6000	20/200	5/200	larger, fibrous change	4 (12, 16, 28)	25 m
9	50 yo, M, PXE	OS	17 m	2800	20/200	20/100	larger, fibrous change	5 (16, 18, 16, 15)	28 m

BCVA = best-corrected visual acuity; CF = counting fingers; OD = right eye; OS = left eye; PXE = Pseudoxanthoma elasticum.

*History of previous conventional laser photocoagulation for extra/juxtafoveal choroidal neovascularization with subfoveal recurrence.

†Both eyes with juxtafoveal choroidal neovascularization.

‡Predominantly occult, all others predominantly classic.

specifically for these lesions.⁹ The purpose of this study was to document the anatomic and visual outcomes in a series of patients treated with photodynamic therapy for subfoveal and juxtafoveal CNV due to angioid streaks.

METHODS

A RETROSPECTIVE ANALYSIS OF 11 EYES OF NINE PATIENTS diagnosed with subfoveal and juxtafoveal choroidal neovascularization associated with angioid streaks and treated by the authors from April 2000 through October 2001 was conducted. Fluorescein angiographic criteria, using definitions previously described,^{12,13} included evidence of choroidal neovascularization caused by angioid streaks that extended adjacent to or underneath the center of the foveal avascular zone. Patients ranged in age from 44 to 79 years (mean, 58.2 years). Four eyes had previously undergone conventional laser photocoagulation for extrafoveal and juxtafoveal choroidal neovascularization. All of these eyes developed subfoveal recurrences prompting treatment with verteporfin. All patients underwent color photography, fluorescein angiography, and complete ocular examinations with determination of best-corrected visual acuity (BCVA) both before treatment and at all subsequent follow-up visits. When appropriate, patients underwent further diagnostic testing for associated systemic diseases. After informed consent was obtained, patients were treated with verteporfin according to the standard protocol followed in the Treatment of Age-Related Macular Degeneration with Photodynamic Therapy Investigation (TAP).¹¹ The follow-up period ranged from 5 to 28 months (mean, 17 months). Fluorescein angiography and funduscopic examination were performed at each follow-up visit. Fluorescein angiograms were evaluated for lesion size,

conversion of the CNVM to a fibrous disciform lesion, and leakage of the choroidal neovascular membrane. Re-treatment was performed based on criteria previously established by the TAP study,⁹⁻¹² except in one case in which early re-treatment was performed at 6 weeks. Intervals for re-treatment ranged from 6 to 28 weeks (mean, 15 weeks).

RESULTS

CLINICAL CHARACTERISTICS AND DEMOGRAPHICS OF THE patient population are presented in Table 1. Eleven eyes of nine patients with subfoveal (nine eyes) or juxtafoveal (two eyes) CNV from angioid streaks were treated with photodynamic therapy. Six of these patients were women. Predominantly classic CNV (greater than 50%) occurred in 10 eyes. Lesion size varied from 600 to 6000 μm (mean, 2900 μm). Nine of the eleven eyes displayed conversion of the CNVM into a fibrous disciform lesion by biomicroscopic examination at final follow-up. Enlargement of the CNVM was documented in seven of the 11 eyes by fluorescein angiography at final follow-up (Figures 1-3).

Best-corrected visual acuity before therapy ranged from 20/25 to counting fingers (CF) (mean, 20/400; median, 20/200) and BCVA at final follow-up ranged from 20/20 to CF (mean, 20/600; median, 20/400). Visual acuity of counting fingers was assigned a value of 20/1000 for statistical purposes. Seven eyes had vision of 20/200 or better preoperatively, while at final follow-up, only three eyes maintained this level of vision or better. In five eyes, the BCVA decreased, most notably from 20/25 to 20/400 in one case of a juxtafoveal choroidal neovascular membrane. Of note, in the fellow eye of this patient also with a juxtafoveal neovascular membrane BCVA remained

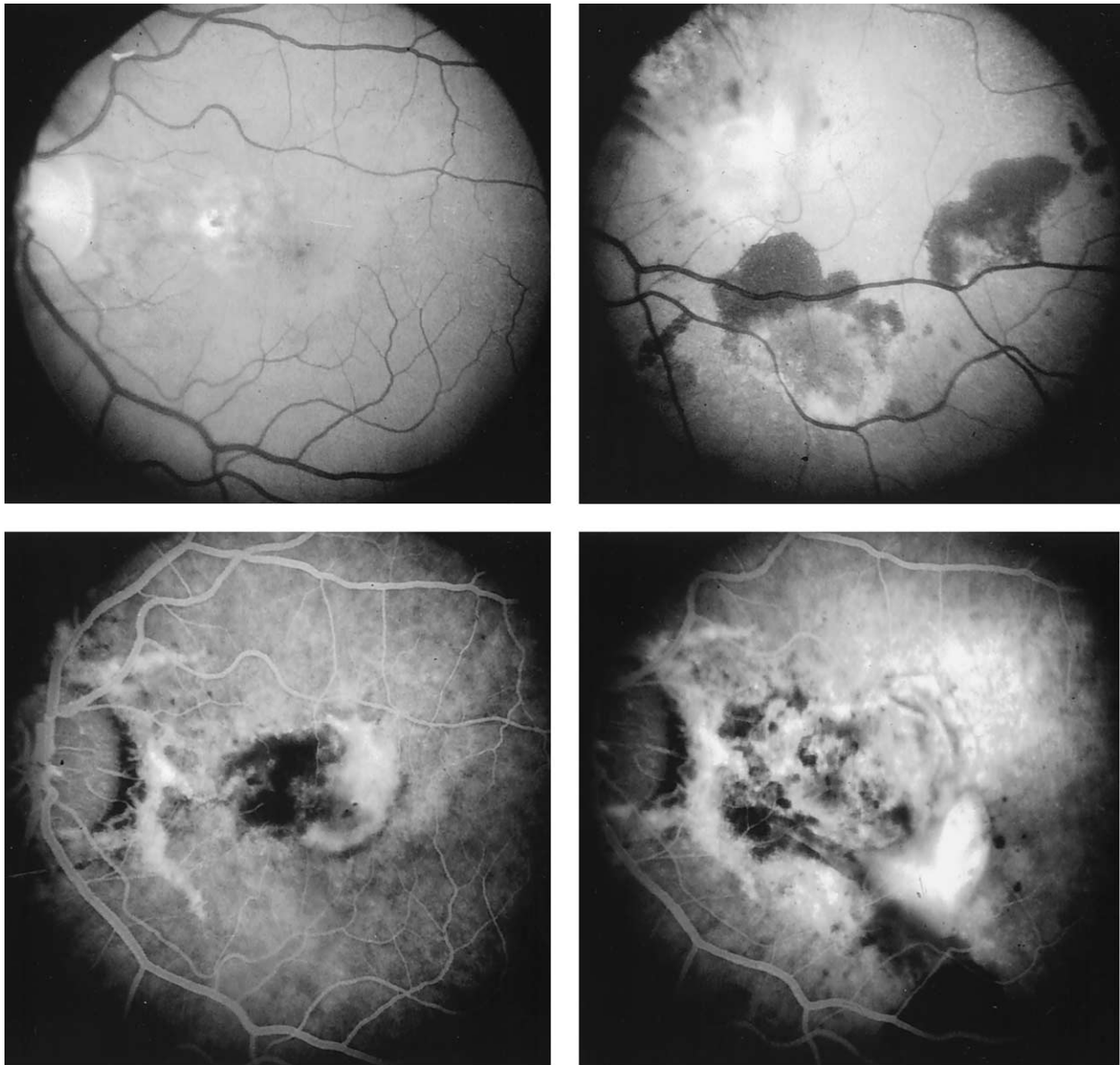


FIGURE 1. Case 2. Pretreatment red-free (top left) and angiographic (bottom left) photos demonstrate subfoveal choroidal neovascular membrane adjacent to previous extrafoveal laser scar. Posttreatment red-free (top right) and angiographic photos (bottom right) at 12 months reveal marked enlargement and disciform conversion of the neovascular complex associated with hemorrhage and leakage.

stable at the 20/20 level with 5 months of follow-up after early re-treatment at 6 weeks (Figure 2). Final BCVA was improved in four of 11 eyes and stable in two of 11 eyes at last follow-up.

Duration from onset of symptoms inclusive of previous conventional laser therapy ranged from 1 week to 6 years (mean, 14.7 months; mode, 1 week) and did not appear to correlate with postoperative visual or anatomic outcome. Additionally, the size of the lesion also did not appear to correlate with final visual or anatomic outcome. All but two eyes were treated multiple times (range, 1–5 treat-

ments; mean, 2.6 treatments). Both of these eyes underwent conversion to a fibrous disciform lesion after the first treatment session.

DISCUSSION

LOSS OF VISION FROM CHOROIDAL NEOVASCULARIZATION is the most serious ocular complication of angioid streaks. Bilateral CNV occurs in 42% to 60% of cases with an

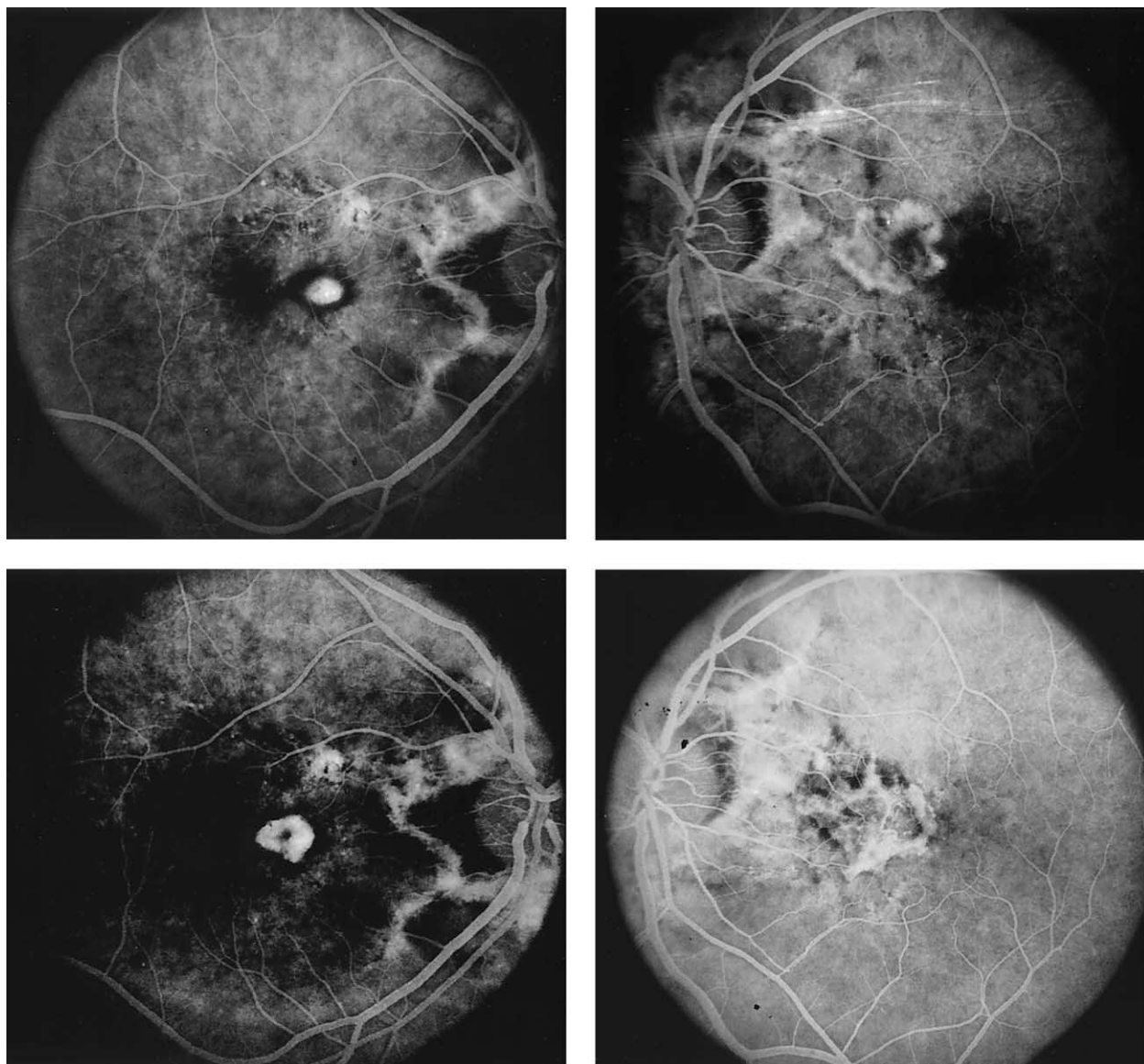


FIGURE 2. Case 5. Pretreatment fluorescein angiogram reveals juxtafoveal choroidal neovascularization (top left) with minimal enlargement before early re-treatment 6 weeks later (bottom left). Fellow eye demonstrates subfoveal extension of juxtafoveal neovascular complex (top right) with increased leakage and fibrous change (bottom right) at 9 months posttreatment angiogram.

interlapsing time of approximately 18 months,⁴ and most patients become legally blind by the age of 50.⁶ Our treatment results are comparable to reported eyes treated for CNV secondary to angioid streaks, although most eyes previously described underwent conventional laser photocoagulation not involving the foveal center as a result of recommendations by the original Macular Photocoagulation Studies.^{4,7,14-18.}

In a series of 21 eyes reported by Piro and associates,⁴ 70% of eyes progressed to legal blindness (55% within 6 months of treatment). Initial visual acuity was 20/40 or better in over 80% of eyes. Lim and associates⁷ in their series of 24 eyes (CNV juxtafoveal in two eyes, subfoveal in three eyes, extrafoveal in 18 eyes, and indeterminate in

one eye) with an initial mean BCVA of 20/50 noted a decreased average visual acuity of 20/120 at final follow-up.⁷ Brancato and associates¹⁷ and Gelisken and associates¹⁸ also reported slightly more favorable outcomes, but it should be noted that in all these series that the initial visual acuity was better and that subfoveal lesions were not included. Recurrence rates were high in both series. In our series of patients treated with photodynamic therapy, a high retreatment rate was similarly noted.

Gelisken and associates¹⁷ noted that lesions in the macula have the worst posttreatment prognosis, and Lim and associates⁷ suggest that the natural history of CNV associated with angioid streaks, even for extrafoveal and juxtafoveal lesions, eventually leads to subfoveal scarring.

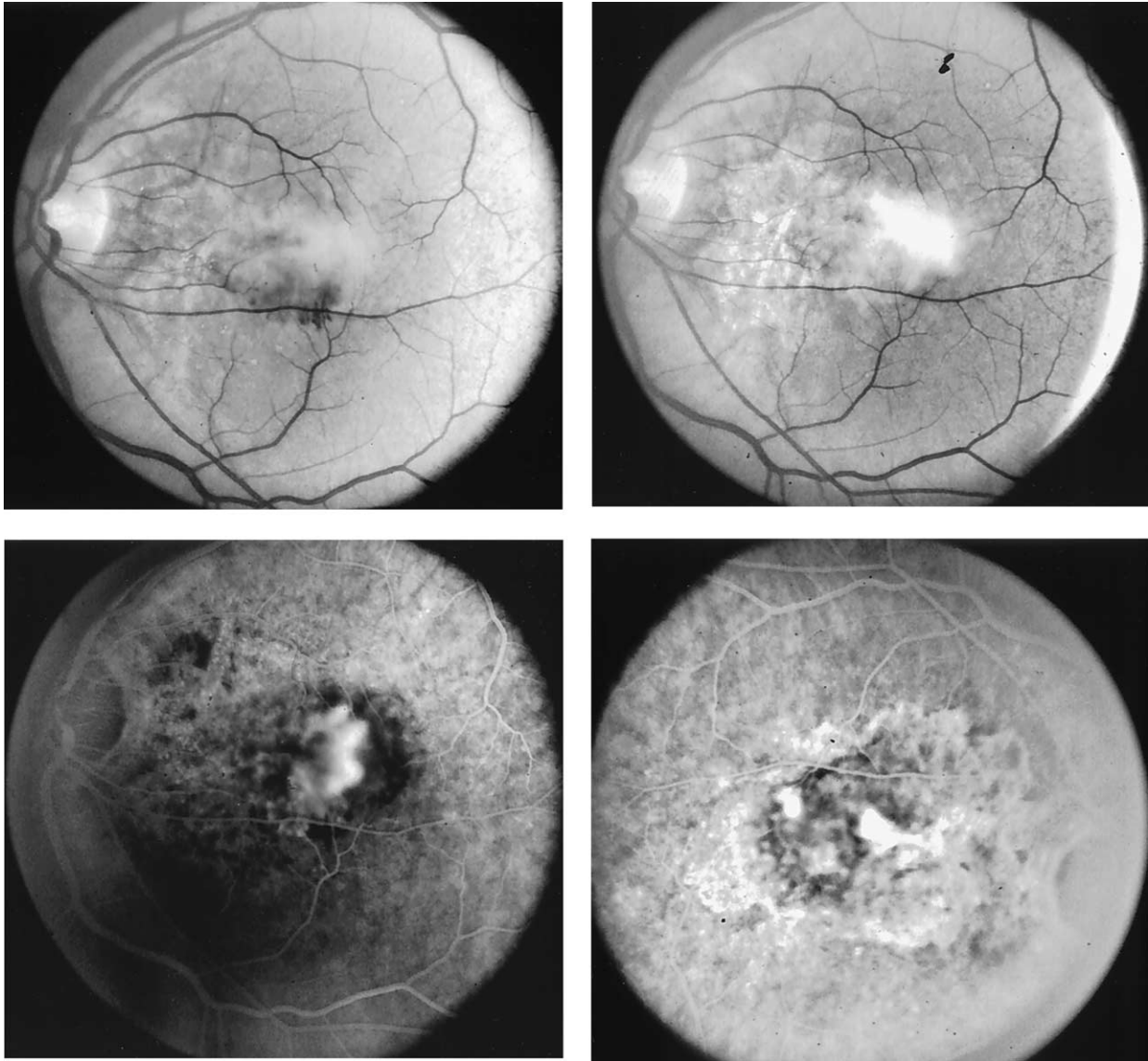


FIGURE 3. Case 9. Pretreatment red-free (top left) and angiographic (bottom left) photos demonstrate subfoveal choroidal neovascular membrane associated with hemorrhage. Posttreatment red-free (top right) and angiographic photos (bottom right) at 8 months reveal marked enlargement, increased leakage, and disciform conversion of the neovascular complex.

Conventional laser photocoagulation of extrafoveal choroidal neovascular lesions has been recommended because treated eyes maintain useful vision for a longer period of time than untreated eyes. Furthermore, it has been recommended that for successful treatment, eyes should be treated as early as possible, and CNV should be treated completely and adequately to not stimulate further neovascularization.¹⁷ Similarly, it is certainly possible that aggressive follow-up with shorter treatment intervals may be more effective in photodynamic therapy of subfoveal or juxtafoveal CNV secondary to angioid streaks. The parameters for follow-up and re-treatment, recommended currently at 3 months, are currently being reevaluated and may lead toward shorter treatment intervals.¹² Of note, in

one of our patients, the first eye with a preoperative BCVA of 20/25 was treated at 3-month intervals with progression of a juxtafoveal choroidal neovascular membrane to a fibrous disciform lesion and final BCVA of 20/400. On review of the patient's history, he was reportedly symptomatic at less than 3 months after initial therapy and probably had recurrence of neovascularization at that time, but did not seek treatment until follow-up at which time retreatment was promptly administered. The second eye was treated more aggressively at 6 weeks, and BCVA has remained stable at 20/20 at final follow-up.

The chronicity of the condition before treatment is notable in many of our patients, most of whom were awaiting approval of photodynamic therapy. We were not

able to correlate duration of neovascularization or history of previous conventional laser therapy with final visual or anatomic outcome. Additionally, size of the neovascular lesions did not appear to correlate with outcome either, although these conclusions are limited by the small size of our series. Our preliminary experience with photodynamic therapy for choroidal neovascularization associated with angioid streaks leads us to believe that it does not significantly alter the course of this disease, with most eyes undergoing enlargement and disciform transformation of the neovascular process. However, aggressive management of these patients with biomicroscopic and fluorescein angiographic examination and timely photodynamic therapy with early re-treatment when indicated may be beneficial in certain cases.

REFERENCES

1. Mansour AM. Systemic associations of angioid streaks. *Ophthalmologica* 1993;207:57–61.
2. Shields JA, Federman JL, Tomer TL, Annesley WH, Jr. Angioid streaks. I. Ophthalmoscopic variations and diagnostic problems. *Br J Ophthalmol* 1975;59:257–266.
3. Connor PH, Juergens JL, Perry HO, et al. Pseudoxanthoma elasticum and angioid streaks: a review of 106 cases. *Am J Med* 1961;30:537–543.
4. Piro PA, Scheraga D, Fine SL. Angioid streaks: natural history and visual prognosis. In Fine SL, Owens SL, editors. *Management of retinal vascular and macular disorders*. Baltimore: Williams & Wilkins, 1983:136–139.
5. Hochart G, Turut P, Francois P. Evolution spontanée des neovaisseaux sous-retiniens dans les stries angioides. *Bull Soc Ophthalmol Fr* 1987;87:289–290.
6. Clarkson JG, Altman RD. Angioid streaks. *Surv Ophthalmol* 1982;26:235–246.
7. Lim JI, Bressler NM, Marsh MJ, Bressler SB. Laser treatment of choroidal neovascularization in patients with angioid streaks. *Am J Ophthalmol* 1993;116:414–423.
8. Roth DB, Estafanous M, Lewis H. Macular translocation for subfoveal choroidal neovascularization in angioid streaks. *Am J Ophthalmol* 2001;131:390–392.
9. Sickenberg M, Schmidt-Erfurth U, Miller JW, et al. A preliminary study of photodynamic therapy using verteporfin for choroidal neovascularization in pathologic myopia, ocular histoplasmosis syndrome, angioid streaks, and idiopathic causes. *Arch Ophthalmol* 2000;118:327–336.
10. Miller JW, Schmidt-Erfurth U, Sickenberg M, et al. Photodynamic therapy with verteporfin for choroidal neovascularization caused by age-related macular degeneration: results of a single treatment in a phase 1 and 2 study. *Arch Ophthalmol* 1999;117:1161–1173.
11. Schmidt-Erfurth U, Miller JW, Sickenberg M, et al. Photodynamic therapy of choroidal neovascularization caused by age-related macular degeneration: results of retreatments in a phase 1 and 2 study. *Arch Ophthalmol* 1999;117:1177–1187.
12. TAP Study Group. Photodynamic therapy of subfoveal choroidal neovascularization in age-related macular degeneration with verteporfin: one-year results of 2 randomized clinical trials. TAP Report 1. *Arch Ophthalmol* 1999;117:1329–1345.
13. Macular Photocoagulation Study Group. Subfoveal neovascular lesions in age-related macular degeneration: guidelines for evaluation and treatment in the Macular Photocoagulation Study. *Arch Ophthalmol* 1991;109:1242–1257.
14. Macular Photocoagulation Study Group. Five-year follow-up of fellow eyes of individuals with ocular histoplasmosis and unilateral extrafoveal or juxtafoveal choroidal neovascularization. *Arch Ophthalmol* 1996;114:677–688.
15. Macular Photocoagulation Study Group. Krypton laser photocoagulation for idiopathic neovascular lesions. Results of a randomized clinical trial. *Macular Photocoagulation Study Group. Arch Ophthalmol* 1990;108:832–837.
16. Macular Photocoagulation Study Group. Argon laser photocoagulation for neovascular maculopathy. Five-year results from randomized clinical trials. *Arch Ophthalmol* 1991;109:1109–1114.
17. Gelisken O, Hendrikse F, Deutman AF. A long-term follow-up study of laser coagulation of neovascular membranes in angioid streaks. *Am J Ophthalmol* 1988;105:299–303.
18. Brancato R, Menchini U, Pece A, Davi G, Capoferri C. Laser treatment of macular subretinal neovascularizations in angioid streaks. *Ophthalmologica* 1987;195:84–87.