

Images in Allergy and Immunology

Qutayba Hamid, MD, PhD, Editor

Eosinophils in allergic inflammation

Editor's note: This feature, Images in allergy and immunology, is designed to highlight current concepts of the immunopathology of allergic diseases and other common immunologically mediated diseases. The presentation will appear as sets of images that involve cross-pathology, histopathology, and molecular pathology and will cover a range of topics of interest to allergists and immunologists.

Eosinophils are the hallmark of allergic inflammation of the airways. They can be detected in the mucosa of the upper and lower airways, and their number has been shown to correlate with disease severity and response to treatment. Fig 1 is an example of major basic protein (MBP) immunostaining of endobronchial biopsy specimens from a patient with mild-to-moderate asthma. Fig 2 is an example of MBP immunostaining in a biopsy specimen from a patient

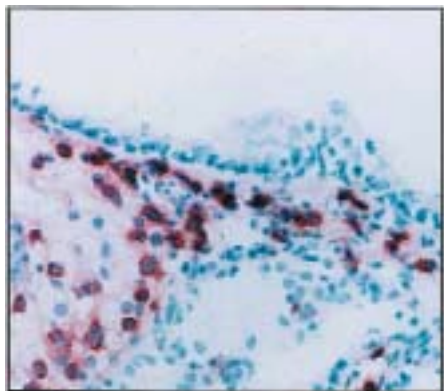


FIG 1

From McGill University, Meakins-Christie Laboratory.
Received for publication October 28, 2003; accepted for publication October 29, 2003.

Reprint requests: Qutayba Hamid, MD, PhD, McGill University, Meakins-Christie Laboratory 3626 St Urbain St, Montreal H2X2P2, Canada.

0091-6749/\$30.00

© 2004 American Association of Allergy, Asthma and Immunology
doi:10.1016/j.jaci.2003.10.058

with severe asthma (note the large number of eosinophils). Eosinophils are also present in the mucosa of the upper airway in patients with rhinosinusitis and can be detected within the epithelium and in the subepithelial region (Fig 3). Eosinophils originate in the bone marrow and are differentiated from CD34/IL-5R progenitor cells (Fig 4). They migrate to

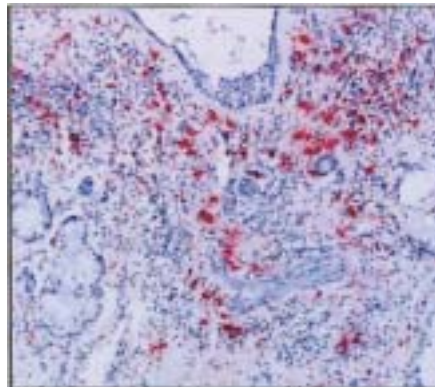


FIG 2

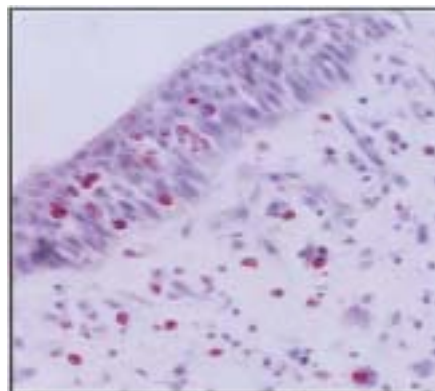


FIG 3

the tissue by adhering to the endothelium (Fig 5) before passing to the tissue with the help of chemoattractants, including chemokines, that are produced mainly by epithelium (Fig 6). Recently, it has been shown that tissue eosinophils could be partially caused by local differentiation of eosinophil progenetics in response to antigen challenge. Fig 7 is an example of MBP immunostaining of upper airway mucosa out of

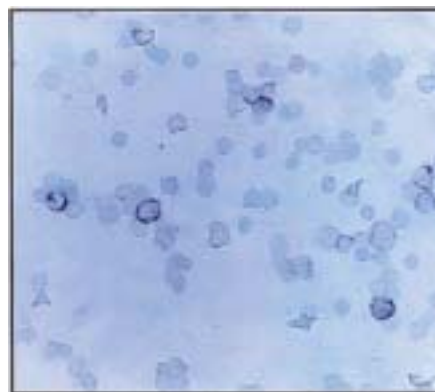


FIG 4

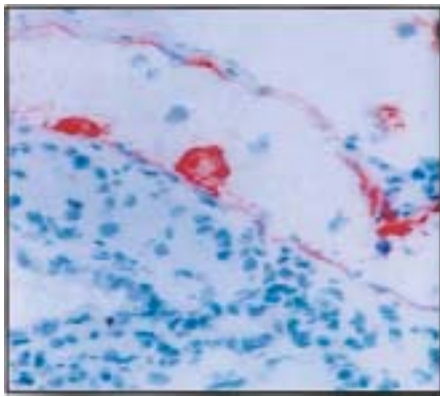


FIG 5

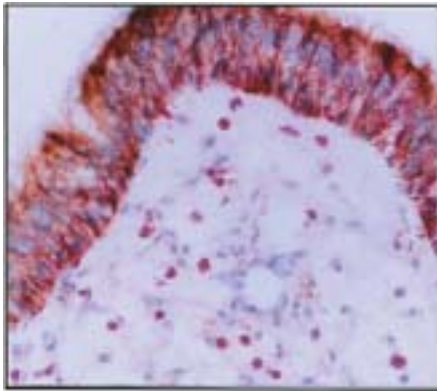


FIG 6

season. Fig 8 is the same tissue after ex vivo challenge with antigen (explant system; note the large number of eosinophils in the absence of cell recruitment).

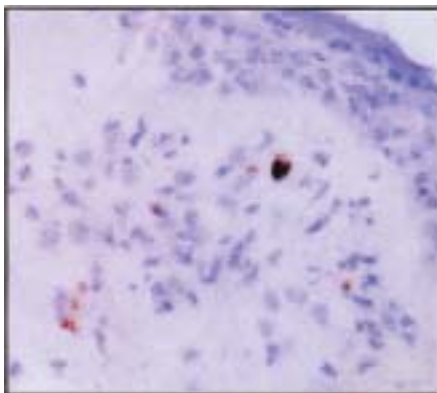


FIG 7

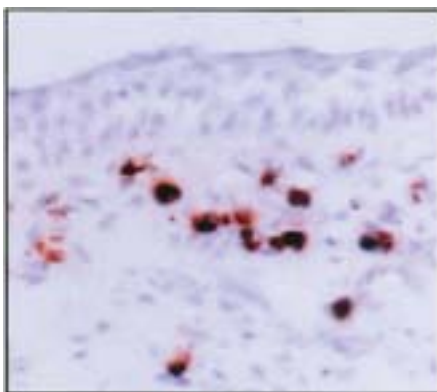


FIG 8

Eosinophils can produce a large number of mediators, cytokines (including T_H1/T_H2 cytokines), and chemokines. Fig 9 is an example of peripheral blood eosinophils from an asthmatic subject immunostained with antibody to IL-9. Fig 10 is an example of in situ hybridization of eosinophils showing positive mRNA for IL-12. Eosinophils can also produce

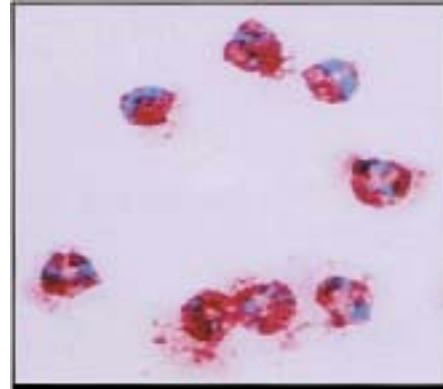


FIG 9

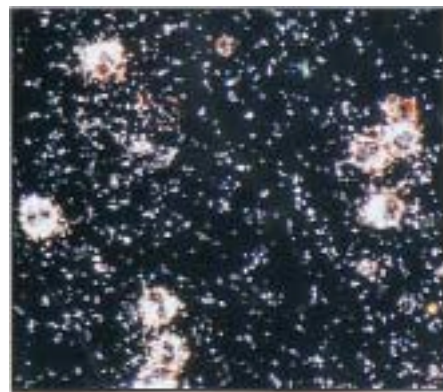


FIG 10

a number of profibrotic cytokines, including TGF- β (Fig 11) and IL-11 (Fig 12), and were suggested to play a role in airway remodeling.

Eosinophils express receptors for a number of T_H2/T_H1 cytokines at the mRNA and protein level. Fig 13 is digoxigenin in situ hybridization of peripheral blood eosinophils from an asthmatic subject

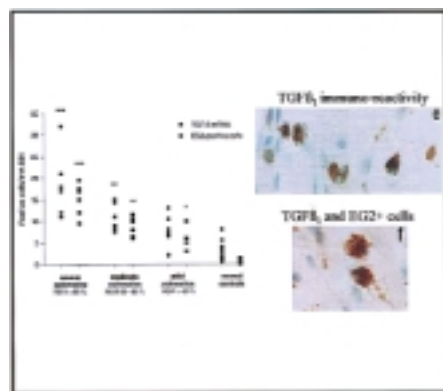


FIG 11

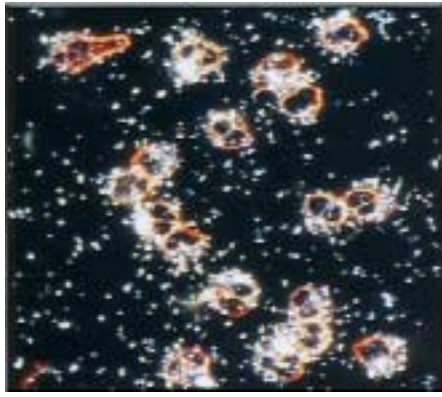


FIG 12

showing positive mRNA for IL-12 receptor. Fig 14 is a confocal microscopy of eosinophils hybridized with fluorescent labeled IL-5 receptor probe. Fig 15 represents simultaneous immunocytochemistry-in situ

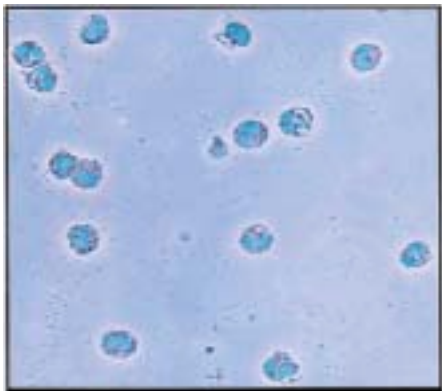


FIG 13

hybridization showing MBP immunoreactivity (green), soluble IL-5 receptor mRNA (red), and membrane-bound IL-5R mRNA (yellow). Fig 16 shows immunocytochemical staining of peripheral blood eosinophils showing positive signal for IL-9 receptor.

Eosinophils can also be present in other tissues from allergic individuals. Fig 17 is an example of MBP immunostaining of sections from a patient with atopic dermatitis. Fig 18 shows eosinophils in the duodenum of a patient with eosinophilic gastroenteritis.



FIG 14

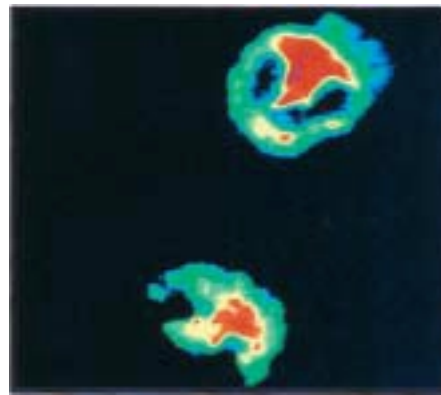


FIG 15

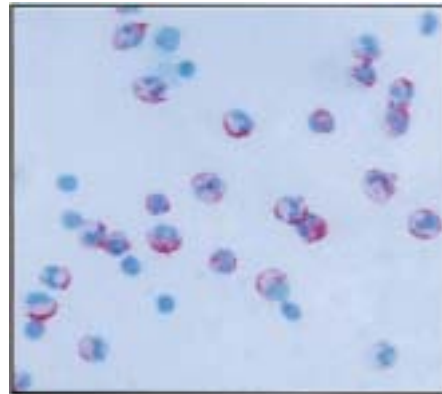


FIG 16

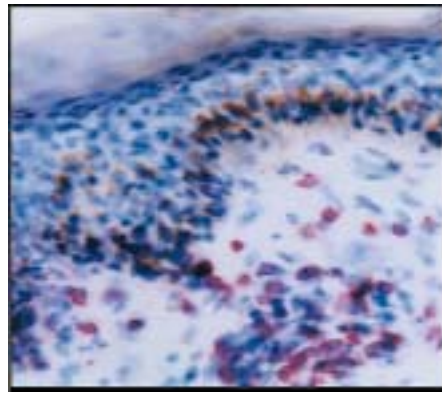


FIG 17

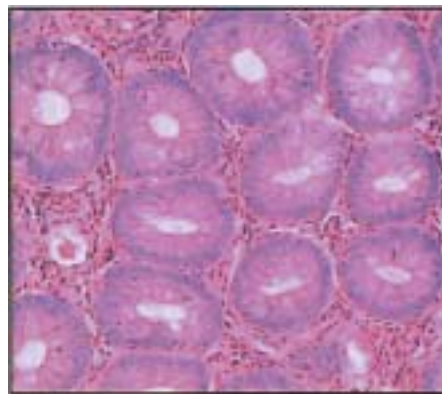


FIG 18