

Tristan Hartzell, MD
Bruce Barlam, MD

From the Department of Surgery, Division of Plastic Surgery, Brigham and Women's Hospital, Boston, MA (Hartzell); and the Department of Surgery, Division of Cardiothoracic Surgery, North Shore Medical Center, Salem, MA (Barlam).

0196-0644/\$-see front matter
Copyright © 2008 by the American College of Emergency Physicians.
doi:10.1016/j.annemergmed.2007.06.485

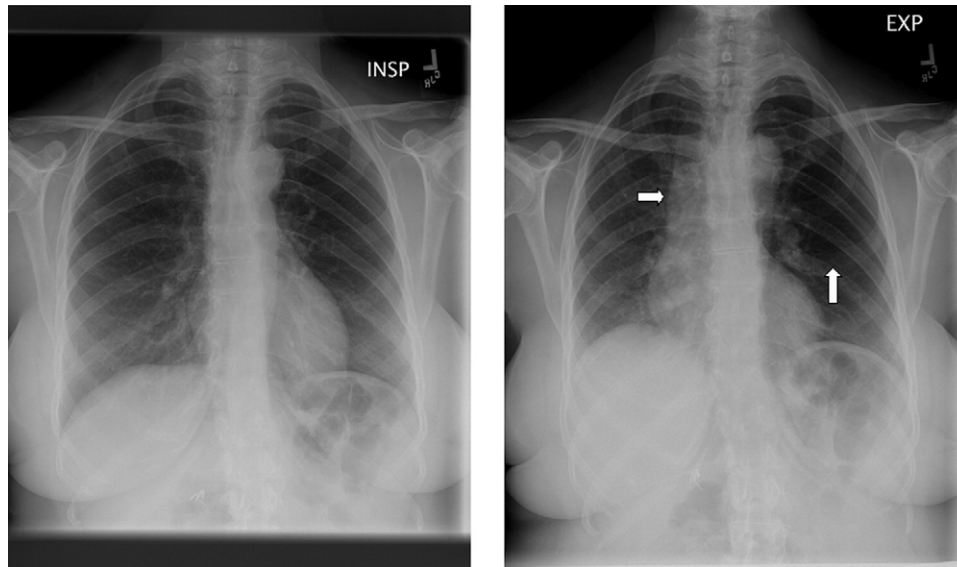


Figure. Anteroposterior inspiratory (left) and expiratory (right) chest radiographs demonstrating mediastinal shift and lucency (arrows) in the expiratory radiograph. Used with permission of Tristan Hartzell, MD, Department of Surgery, Division of Plastic Surgery, Brigham and Women's Hospital, Boston, MA.

[Ann Emerg Med. 2008;51:126.]

A 57-year-old woman with no significant medical history presented to our emergency department with shortness of breath and audible wheezing. Two hours before presentation, she had been conversing while eating a carrot when she felt as if she aspirated. In our hospital, she was dyspneic but acyanotic. On auscultation, she had inspiratory wheezing on the left side greater than the right side. Inspiratory and expiratory chest radiographs demonstrated mediastinal shift and air trapping in the left lung on expiration (Figure).

*For the diagnosis and teaching points, see page 129.
To view the entire collection of Images in Emergency Medicine, visit www.annemergmed.com*

6. Goldfrank LR, Hoffman RS. The cardiovascular effects of cocaine: update 1992. In: *Acute Cocaine Intoxication: Current Methods and Treatment. National Institute on Drug Abuse Research Monograph Series.* 1993;123:70-109.
7. Sand IC, Brody SL, Wrenn KD, et al. Experience with esmolol for the treatment of cocaine-associated cardiovascular complications. *Am J Emerg Med.* 1991;9:161-163.
8. Dusenberry SJ, Hicks MJ, Mariani PJ. Labetalol treatment of cocaine toxicity. *Ann Emerg Med.* 1987;16:235.
9. Gay GR, Loper KA. The use of labetalol in the management of cocaine crisis. *Ann Emerg Med.* 1988;17:282-283.
10. Gay GR, Loper KA. Control of cocaine-induced hypertension with labetalol. *Anesth Analg.* 1988;67:92.
11. Derlet RW, Albertson TE. Acute cocaine toxicity: antagonism by agents interacting with adrenoceptors. *Pharmacol Biochem Behav.* 1990;36:225-231.
12. Kenny D, Pagel PS, Warltier DC. Attenuation of the systemic and coronary hemodynamic effects of cocaine in conscious dogs: propranolol versus labetalol. *Basic Res Cardiol.* 1992;87:465-477.
13. Trouve R, Nahas GG. Antidotes to lethal cocaine toxicity in the rat. *Arch Int Pharmacodyn Ther.* 1990;305:197-207.
14. Smith M, Garner D, Niemann JT. Pharmacologic interventions after an LD50 cocaine insult in a chronically instrumented rat model: are beta-blockers contraindicated? *Ann Emerg Med.* 1991;20:768-771.
15. National Quality Measures Clearinghouse. Acute myocardial infarction: percent of patients without beta blocker contraindications who received a beta blocker within 24 hours after hospital arrival. Available at: http://www.qualitymeasures.ahrq.gov/summary/summary.aspx?doc_id=6054. Accessed July 4, 2007.
16. Joint Commission on Accreditation of Healthcare Organizations. Beta blockers for acute myocardial infarction. Available at: <http://www.jointcommission.org/NR/rdonlyres/AB92B013-B9A7-48AC-8AC6-759410D6E791/0/COMMITBetaBlockerFACTSheet.pdf>. Accessed July 4, 2007.
17. Chen ZM, Pan HC, Chen YP, et al; COMMIT (CLOpidogrel and Metoprolol in Myocardial Infarction Trial) Collaborative Group. Early intravenous then oral metoprolol in 45,852 patients with acute myocardial infarction: randomised placebo-controlled trial. *Lancet.* 2005;366:1622-1632.
18. Hollander JE, Hoffman RS. Cocaine-induced myocardial infarction: an analysis and review of the literature. *J Emerg Med.* 1992;10:169-177.
19. Hollander JE, Hoffman RS, Gennis P, et al. Prospective multicenter evaluation of cocaine-associated chest pain. Cocaine Associated Chest Pain (COCHPA) Study Group. *Acad Emerg Med.* 1994;1:330-339.
20. Hollander JE, Hoffman RS, Burstein JL, et al. Cocaine-associated myocardial infarction. Mortality and complications. Cocaine-Associated Myocardial Infarction Study Group. *Arch Intern Med.* 1995;155:1081-1086.
21. Weber JE, Chudnofsky CR, Boczar M, et al. Cocaine-associated chest pain: how common is myocardial infarction? *Acad Emerg Med.* 2000;7:873-877.
22. Hollander JE, Hoffman RS, Gennis P, et al. Cocaine-associated chest pain: one-year follow-up. *Acad Emerg Med.* 1995;2:179-184.
23. Lange RA, Cigarroa RG, Flores ED, et al. Potentiation of cocaine-induced coronary vasoconstriction by beta-adrenergic blockade. *Ann Intern Med.* 1990;112:897-903.
24. Lange RA, Cigarroa RG, Yancy CW Jr, et al. Cocaine-induced coronary-artery vasoconstriction. *N Engl J Med.* 1989;321:1557-1562.
25. Boehrer JD, Moliterno DJ, Willard JE, et al. Influence of labetalol on cocaine-induced coronary vasoconstriction in humans. *Am J Med.* 1993;94:608-610.
26. Albertson TE, Dawson A, de Latorre F, et al; American Heart Association; International Liaison Committee on Resuscitation. TOX-ACLS: toxicologic-oriented advanced cardiac life support. *Ann Emerg Med.* 2001;37(4 suppl):S78-90.
27. Dattilo PB, Hailpern SM, Fearon K, et al. β -blockers are associated with reduced risk of myocardial infarction after cocaine use. *Ann Emerg Med.* 2008;51:117-125.
28. Merigian KS, Park LJ, Leeper KV, et al. Adrenergic crisis from crack cocaine ingestion: report of five cases. *J Emerg Med.* 1994;12:485-490.
29. Leikin JB. Cocaine and beta-adrenergic blockers: a remarriage after a decade-long divorce? *Crit Care Med.* 1999;27:688-689.
30. Weiss RD, Gawin FH. Protracted elimination of cocaine metabolites in long-term high-dose cocaine abusers. *Am J Med.* 1988;85:879-880.
31. Fared FN, Chan GM, Hoffman RS. Death temporally related to the use of a beta adrenergic receptor antagonist in cocaine associated myocardial infarction. *J Med Toxicol.* 2007;3:169-172.

IMAGES IN EMERGENCY MEDICINE

(continued from p. 126)

DIAGNOSIS:

Foreign body aspiration. The patient was diagnosed with a foreign body aspiration and taken to the operating room. A flexible bronchoscopy was performed, and a large piece of carrot wedged in the proximal portion of the left main bronchus was removed. The patient had no significant issues postoperatively and was discharged home 1 day after her presentation.

A single inspiratory chest radiograph has a low sensitivity for diagnosing foreign-body aspiration acutely. The foreign bodies are frequently radiolucent, and atelectasis can take more than a day to develop. One diagnostic technique frequently used in children and adults unable to give a medical history is inspiratory and expiratory chest radiographs. Expiratory views are often able to better demonstrate air trapping than a single radiograph on inspiration. Signs include increased lucency, mediastinal shift, and a depressed diaphragm.