

Yu-Tse Tsan, MD
Sung-Yuan Hu, MD
Tzu-Chieh Lin, MD

From the Department of Emergency Medicine, Taichung Veterans General Hospital, Taiwan, Republic of China (Tsan, Hu, Lin); Chung Shan Medical University, Taiwan, Republic of China (Tsan, Hu, Lin); and the National Taichung Nursing College, Taiwan, Republic of China (Hu).

0196-0644/\$-see front matter

Copyright © 2008 by the American College of Emergency Physicians.

doi:10.1016/j.annemergmed.2008.05.022

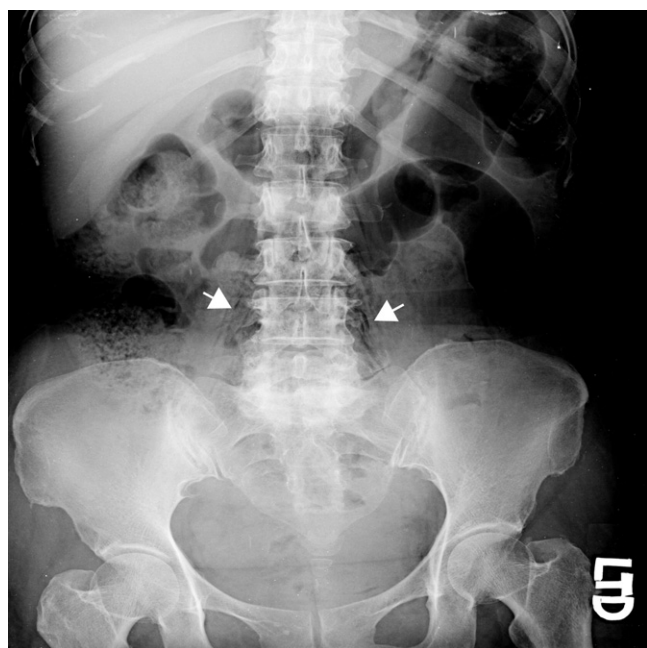


Figure 1. The abdominal radiograph presenting free gas bubbles in the soft tissue over the paravertebral and retroperitoneal regions (arrows), with discal degeneration and space narrowing at the lumbar to sacral vertebrae.

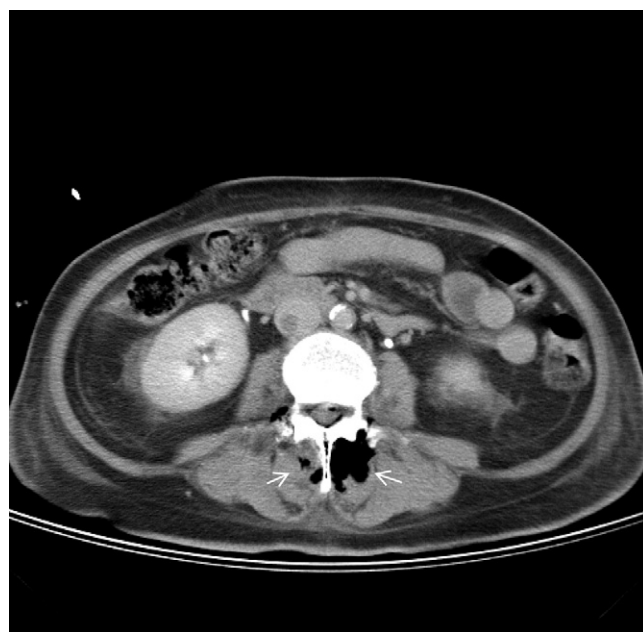

Figure 2. CT scan of the abdomen and pelvis, with oral and intravenous contrast showing multifoci of air bubbles in back muscles beside the vertebra (arrows). Used with permission of Yu-Tse Tsan, MD, Department of Emergency Medicine, Taichung Veterans General Hospital, Taiwan, Republic of China.

[Ann Emerg Med. 2009;53:284.]

A 53-year-old woman, with no pertinent medical history, presented to the emergency department, complaining of severe low back pain, general malaise, and bilateral thigh weakness for 2 days. She reported intermittent episodes of fever and progressively worsening low back pain during 3 weeks. Physical examination revealed lumbar and sacral tenderness. Laboratory evaluation revealed that the WBC count was $19,100 \text{ cells/mm}^3$, segmented neutrophils 96%, and the C-reactive protein 23.3 mg/dL (normal $<0.4 \text{ mg/dL}$). An abdominal radiograph (Figure 1) was obtained.

For the diagnosis and teaching points, see page 294.

To view the entire collection of Images in Emergency Medicine, visit www.annemergmed.com

IMAGES IN EMERGENCY MEDICINE

(continued from p. 284)

DIAGNOSIS:

Pyogenic vertebral osteomyelitis with bilateral paravertebral abscesses. Computed tomographic (CT) scan of the abdomen and pelvis is shown in [Figure 2](#). It displays multifoci of air bubbles in back muscles beside the vertebra. On the patient's admission, the abscesses were drained percutaneously, and culture revealed *Escherichia coli*. We treated with ceftriaxone for 6 weeks. Acid-fast stain results were negative. The patient was discharged in stable condition.

A high index of suspicion is necessary in detecting pyogenic vertebral osteomyelitis because delays in diagnosis are common. Contiguous spread of infection can lead to paravertebral, subdural, retroperitoneal, or psoas abscesses.¹ The major clinical manifestation is back pain, but fever is inconsistent. C-reactive protein is increased in 90% or more of patients.² Radiographs will reveal the degree of bony destruction, and an early change can be disc space narrowing in nearly 75% of patients. Soft tissue extension must be suspected in the presence of an abnormal psoas shadow, widening of the mediastinum, or enlargement of the retropharyngeal soft tissue window. CT is the preferred imaging modality, given the high sensitivity and rapidity. CT provides detail of bony anatomy and also can identify the presence of adjacent soft tissue masses or abscesses.³ Magnetic resonance imaging is the most sensitive radiologic technique. Sensitivity, specificity, and accuracy are reported as 96%, 92%, and 94%, respectively.⁴ CT-guided needle biopsy is generally necessary to confirm the suspicion. Treatment is with surgical drainage and empiric antibiotics according to the probable origin of infection.⁵

REFERENCES

1. Bass SN, Ailani RK, Shekar R, et al. Pyogenic vertebral osteomyelitis presenting as exudative pleural effusion: a series of five cases. *Chest*. 1998;114:642-647.
2. Carragee EJ. Pyogenic vertebral osteomyelitis. *J Bone Joint Surg Am*. 1997;79:874-880.
3. An HS, Seldomridge JA. Spinal infections: diagnostic tests and imaging studies. *Clin Orthop Relat Res*. 2006;444:27-33.
4. Modic MT, Feiglin DH, Piraino DW, et al. Vertebral osteomyelitis: assessment using MR. *Radiology*. 1985;157:157-166.
5. Kuklo TR, Potter BK, Bell RS, et al. Single-stage treatment of pyogenic spinal infection with titanium mesh cages. *J Spinal Disord Tech*. 2006;19:376-382.

IMAGES IN EMERGENCY MEDICINE

(continued from p. 285)

DIAGNOSIS:

Osteochondroma. Osteochondromas are benign bony growths with a cartilage cap that usually originate from long bones. They are typically oriented nearly parallel with their neighboring long bone, with their axis pointing away from the nearest joint. New growth extends from the tumor's cartilage cap. Because the cartilage cap is radiolucent, the lesion typically appears smaller on radiography than on physical examination.¹

Most osteochondromas are diagnosed incidentally, but some may become symptomatic as they place pressure on adjacent muscles, bursae, or nerves. Less than 1% of these growths become malignant. Management is typically conservative. Surgery is reserved for those patients who have significant pain or restriction of joint mobility.² In children, radiographs of other areas of the body may be indicated to exclude osteochondromatosis, an autosomal dominant condition resulting in multiple osteochondromas, and an increased risk of malignant change. In this case, the patient's fractured osteochondroma (best seen in [Figure 3](#)) was treated with crutches, analgesics, and orthopedic follow-up.

REFERENCES

1. Grainger R, Allison D. Grainger & Allison's Diagnostic Radiology: A Textbook of Medical Imaging. 4th ed. Philadelphia: Elsevier Churchill Livingstone: 2001.
2. Canale S, Beaty J. Campbell's Operative Orthopaedics. 10th ed. Philadelphia: Mosby Elsevier: 2003.