

Erratum

Airway Management in Trauma: An Update

John McGill, MD^{a,b}

^a*Department of Emergency Medicine, Hennepin County Medical Center, 701 Park Avenue North, Minneapolis, MN 55415, USA*

^b*Department of Emergency Medicine, University of Minnesota, Minneapolis, MN, USA*

The above article, which appeared in the August 2007 issue “Current Concepts in the Management of the Trauma Patient,” contained an unfortunate error in Fig. 2C. The correct representation of this figure appears below.

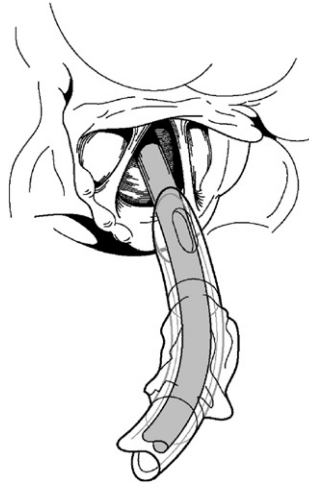


Fig. 2. (C) The bevel of the ET tube is facing posteriorly and allows for smooth passage through the glottis.