

Wiktor Stent for Treatment of Chronic Total Coronary Artery Occlusions: Short- and Long-Term Clinical and Angiographic Results From a Large Multicenter Experience

ANGELO ANZUINI, MD, SALVATORE ROSANIO, MD, PhD,* VICTOR LEGRAND, MD, PhD, FESC,†
MONICA TOCCHI, MD,‡ RENATO COPPI, PhD,‡ HANS BONNIER, MD,§ IMAD SHEIBAN, MD,
HENRI E. KULBERTUS, MD, PhD, FESC,† SERGIO L. CHIERCHIA, MD, FESC

Milan and Rome, Italy; Liege, Belgium; and Eindhoven, The Netherlands

Objectives. This study reports the first multicenter experience with the Wiktor coil stent for treatment of chronic total coronary artery occlusions (CTOs).

Background. Percutaneous transluminal coronary angioplasty (PTCA) of CTO is associated with very high restenosis and reocclusion rates. Coronary stenting has been proposed as a means of improving outcome. However, the Wiktor device for CTOs has never been tested in a large patient sample.

Methods. From January 1993 to December 1996, 89 patients with 91 CTOs underwent Wiktor stent implantation after successful PTCA. The post-stenting regimen consisted of warfarin (Coumadin) plus aspirin in the initial 49 patients (55%) and aspirin plus ticlopidine in 40 patients (45%).

Results. Stenting was successful in 87 patients (98%). At 1 month, 6% of patients had subacute stent thrombosis, 3% had a major bleeding event, and 1% had access-site complications. Subacute stent thrombosis showed univariate association with

warfarin therapy ($p = 0.009$). Angiographic follow-up was obtained in 76 (93%) of 82 eligible patients. The restenosis rate was 32%, including 4% reocclusions. By multiple logistic regression analysis, restenosis was independently associated with multiple stents (adjusted odds ratio [OR] 27.67, 95% confidence interval [CI] 4.25 to 79.95, $p = 0.0008$) and increasing values of occlusion length (adjusted OR 1.23, 95% CI 1.09 to 1.39, $p = 0.001$). Freedom from death, myocardial infarction or stented vessel revascularization was 87% and 72% at 1 and 3 years, respectively.

Conclusions. Short- and long-term clinical and angiographic outcomes are favorable in patients undergoing Wiktor stent implantation in CTO. Further technical improvement is needed to reduce the restenosis rate in patients with long lesions and multiple stents.

(J Am Coll Cardiol 1998;31:281-8)

©1998 by the American College of Cardiology

Chronic total coronary artery occlusions (CTOs) account for 10% to 20% of all percutaneous transluminal coronary angioplasty (PTCA) procedures at centers with high procedural volumes, and these lesions pose a management dilemma for the interventional cardiologist (1). Although substantial advances in PTCA devices and improvement in operators' skill have yielded a successful recanalization in ~80% of CTOs, a restenosis rate of 44% to 77% limits the long-term benefit of PTCA (1,2). Many patients with CTOs are therefore referred for coronary artery bypass graft surgery (CABG), even in the presence of single-vessel disease. Recently, coronary artery

stenting has emerged as a valuable therapeutic strategy for the management of CTO (3-7). Intracoronary insertion of the Palmaz-Schatz stent or the new, less shortening Wallstent after successful PTCA of CTO has been associated with favorable restenosis and reocclusion rates, improved anginal status and a reduced need for late CABG (3-7). In the early 1990s, the balloon-expandable, helicoid coil, low mass, radiopaque Wiktor stent became available for clinical investigation (8). This device has been successfully used for restenotic lesions, bailout situations, native coronary arteries and vein graft disease (9-12). However, no study has so far tested the safety and effectiveness of the Wiktor stent for treatment of CTO. This study reports the short- and long-term clinical and angiographic outcomes of Wiktor stent implantation in a large series of patients with CTO.

Methods

Study patients. Between January 1993 and December 1996, 89 patients with 91 CTOs underwent Wiktor stent implantation after successful recanalization by PTCA. Patients were selected who had 1) angina pectoris with evidence of

From the Department of Cardiology, San Raffaele Hospital, Milan, Italy; †Hopital Cardiologique Universitaire, Liege, Belgium; ‡Department of Cardiology and Department of Statistics, La Sapienza University, Rome, Italy; and §Department of Cardiology, Catharina Hospital, Eindhoven, The Netherlands. This study was presented in part at the 70th Annual Scientific Sessions of the American Heart Association, Orlando, Florida, November 1997.

Manuscript received July 9, 1997; revised manuscript received October 3, 1997, accepted October 23, 1997.

*Present address and address for correspondence: Dr. Salvatore Rosanio, Division of Cardiology, John Sealy Hospital, Room 5.106, University of Texas Medical Branch at Galveston, 301 University Boulevard, Galveston, Texas 77555-0533. E-mail: sarosani@utmb.edu.

Abbreviations and Acronyms

CABG	= coronary artery bypass graft surgery
CI	= confidence interval
CTO	= chronic total (coronary artery) occlusion
MI	= myocardial infarction
OR	= odds ratio
PTCA	= percutaneous transluminal coronary angioplasty
SST	= subacute stent thrombosis
TIMI	= Thrombolysis in Myocardial Infarction

myocardial ischemia demonstrated by electrocardiographic changes or positive results on stress testing; or 2) postinfarct myocardial viability assessed either by dobutamine echocardiography or thallium single-photon emission computed tomography. Patients having had a previous revascularization procedure (PTCA or CABG) or myocardial infarction (MI) within 1 month of the procedure were excluded. Lesion-related criteria for exclusion were a reference diameter <2.5 mm by visual estimation and the presence of angiographically visible thrombus adjacent to the occlusion site. A CTO was defined as complete interruption of the vessel, with either Thrombolysis in Myocardial Infarction (TIMI) flow grade 0 (absolute occlusion) or TIMI flow grade 1 (functional occlusion), that was >1 month old. The occlusion age was estimated either from the date of MI in the distribution of the occluded vessel, abrupt worsening of angina pectoris or information provided by sequential angiograms when these were available. All patients gave written, informed consent to the procedure. In addition, at the time of initial stent implantation, patients were informed about the need for 6-month angiographic and late clinical follow-up. All patients included in this study had at least 12 months of follow-up.

Stent implantation procedure. Premedication consisted of oral, non-enteric-coated aspirin, 325 mg/day, and calcium channel blocking agents. A bolus of 10,000 U of heparin was administered after sheath insertion with a repeat bolus given as needed to maintain an activated clotting time >250 s. Patients were not given dextran or dipyridamole before, during or after the stent procedure. All patients underwent PTCA by a standard technique in which the femoral approach was used. The choice of guide wires, balloon type and brand and the number and pressure of the inflations were left to the discretion of the operator. Once the vessel was opened and the guide wire was identified within the true lumen distal to the occlusion, one or more Wiktor stents were implanted under fluoroscopic guidance with the aim to cover the entire lesion. The Wiktor stent (Medtronic Inc.) is a balloon-expandable stent composed of a single, loose-interdigitating, coil-like tantalum wire (0.125 mm in diameter), formed into a sinusoidal wave and configured as a helix. Tantalum confers good radiopacity. The prosthesis, 14 to 16 mm long, is premounted on a polyethylene semicompliant balloon. The maximal diameter of the balloon during inflation determines the final size of the prosthesis. The crimped stent profile is ~ 1.5 mm and deploy-

ment does not induce any modification in stent length. Stent deployment was performed using an initial inflation of 8 atm. Stent expansion was completed by additional inflations (maximal 14 atm), using the same balloon with the central marker positioned at the distal and proximal ends of the device, until good angiographic result was obtained. The result was considered inadequate if dissection flaps were not completely covered by stent struts. When multiple stents were required to treat a long lesion or newly developed coronary dissection, distal stents were usually placed first, but occasionally a single proximal stent was placed first to eliminate the distal extension of the false lumen. Overlapping or telescoping of sequential stents was used only when additional radial support was deemed advantageous; otherwise stents were implanted to ensure minimal overlap and no gaps. Intravascular ultrasound was not used to avoid possible damage of the Wiktor coil during introduction of the ultrasound catheter. The angiographic success of stenting was assessed off-line by a quantitative estimate of residual coronary stenosis $<30\%$ of the lumen diameter within the stent, effectively positioned at the intended site and by gradation of antegrade flow as a TIMI flow grade 3 perfusion.

Postprocedural medication protocol. The medication protocol was modified over the study period, after the publication of newer guidelines for post-stent treatment. Until early 1994, the first 49 patients (55%) were treated with standard postprocedural anticoagulant therapy. In these patients, on completion of the procedure, heparin was discontinued briefly to allow for sheath removal, then reinstated within 3 to 4 h. Oral anticoagulant therapy (warfarin sodium [Coumadin]) was initiated on the day of the procedure, and both heparin and warfarin were continued until oral anticoagulation resulted in prolongation of prothrombin time to an international normalized ratio of 2.5 to 3.5, after which heparin was stopped. Warfarin was continued for 1 month in association with aspirin, 325 mg/day, which was given indefinitely. As of late 1994, the subsequent 40 patients (45%) received no oral anticoagulant agent. Heparin was discontinued 12 h after the intervention, and ticlopidine, 250 mg twice daily, was started immediately after the procedure and continued for 1 month in association with aspirin, 325 mg/day, which was continued long term. For all patients, nitrates and calcium channel blockers were recommended for at least 6 months.

Quantitative angiographic analysis. Cineangiographic films were processed at a central core laboratory by two experienced operators not involved in the stenting procedure. Angiograms were quantitatively analyzed by the computer-assisted Cardiovascular Measurement System (CMS-Medis Medical Imaging Systems, Nuemen, The Netherlands), using semiautomated edge detection. Intracoronary nitroglycerin (0.1 to 0.2 mg) was injected before all angiographic assessments. End-diastolic cine frames best displaying the lesion with minimal foreshortening and overlay of side branches were selected from among multiple projections and digitized. Quantitative analysis of the follow-up angiogram was performed by using matching views. Absolute measurements were obtained

using the dye-filled catheter (8F for intervention and 6F at follow-up) as a scaling reference. The reference was measured from angiographically normal segments adjacent to the lesion, and the same reference segment was selected before and after intervention and at follow-up. Late lumen loss was measured as the difference between the minimal lumen diameter immediately after stenting and that obtained at follow-up angiography. The loss index was calculated as the ratio of late loss to minimal lumen diameter after stenting. Occlusion length was measured with manual calipers by using information from ipsilateral or contralateral collateral penetration according to a previously reported methodology (2). Measurements of lesion length (in millimeters) were repeated by two operators on a random sample of 45 studies and by the same observer on different days without knowledge of earlier results. No systematic differences were noted between three paired measurements (mean difference 0.70 ± 5.09 mm, $t = 0.84$, $p = 0.7$). Regression of the absolute difference between the length of occlusion on its mean measurement yielded $F = 0.16$ and $p = 0.8$. Recorded angiographic characteristics included the morphologic features of the occlusion (abrupt or tapered); the presence of bridging collateral vessels; calcification on fluoroscopy at the site of the occlusion; and evidence of coronary dissection, defined as marked irregularity of the vessel wall, a lumen filling defect suggestive of intimal flap or extravasation of contrast agent outside the lumen after balloon dilation. Left ventricular ejection fraction was determined by left ventriculography performed with the use of biplane 30° right anterior oblique and 60° left anterior oblique projections. A binary definition of restenosis ($\geq 50\%$ diameter stenosis occurring at the stent site or immediately proximally or distally) and reocclusion (TIMI flow grade 0 or 1) on follow-up angiography was used.

Clinical and angiographic follow-up. Patients were followed up by means of outpatient visits at intervals of 1, 3, 6 and 12 months and yearly thereafter. Telephone contact with the patient or referring physicians was also used when needed for follow-up purposes. Subacute stent thrombosis (SST) was defined as a clinical event, leading to cardiac catheterization, that identified stent vessel occlusion with TIMI flow grade 0 or 1 occurring >24 h and within 1 month of stent deployment. Cardiac events were death, MI or requirement for target vessel revascularization (CABG or PTCA), whichever occurred first. If symptoms recurred before the scheduled 6-month follow-up angiography, an angiogram was obtained earlier. If no definite restenosis or reocclusion was present and the follow-up time was <4 months, the patient was asked to undergo further coronary angiography at 6 months. The primary angiographic end point of the study was the occurrence of restenosis, including reocclusion, after 6 months of follow-up. Follow-up was continued in patients who underwent repeat PTCA for treatment of in-stent restenosis or reocclusion.

Statistics. Continuous measures are expressed as the mean value \pm SD or as the median value and relative ranges; dichotomous variables are presented as percentages. Comparison of binary variables were performed using the Yates-

Table 1. Clinical Characteristics of the 89 Study Patients

Age (yr)	55 \pm 9
Male gender	66 (74)
Hypertension	35 (39)
Cholesterol >200 mg/dl	30 (34)
Diabetes mellitus	26 (29)
Cigarette smoking	48 (54)
CCS angina class \geq III	60 (67)
Previous MI	50 (56)
LVEF (%)	57 \pm 11
Multivessel disease	49 (55)
Estimated occlusion age	
>1 to ≤ 3 months	19 (21)
>3 months	70 (79)
Warfarin therapy	49 (55)

Data are presented as mean value \pm SD or number (%) of patients. CCS = Canadian Cardiovascular Society; LVEF = left ventricular ejection fraction; MI = myocardial infarction.

corrected chi-square statistic or, when appropriate, the Fisher exact test. Continuous variables were compared by one-way analysis of variance. Statistical significance (two-tailed) was inferred at $p < 0.05$. Logistic regression analysis was separately used to assess the contribution of clinical, angiographic and procedural variables to two dichotomous outcomes (i.e., SST and restenosis). Variables affecting restenosis were analyzed in those patients who had angiographic follow-up available for review. Univariate correlates were determined by logistic regression analysis based on the maximum likelihood method. To select covariates independently associated with each outcome, significant univariate predictors were reassessed by forward stepwise multivariate analysis, with values for inclusion and elimination set at $p = 0.05$ and $p = 0.10$, respectively. The likelihood-ratio chi-square value was used to assess multivariate model significance. As a measure of the strength of the association between each multivariate predictor and the outcome variable, an adjusted odds ratio (OR) with corresponding 95% confidence intervals (CIs) was computed from the estimated multiple logistic regression coefficient and standard error. Clinical events were described by the Kaplan-Meier method.

Results

Baseline characteristics. The clinical features of the 89 study patients are presented in Table 1. Most patients were middle-aged men. The majority of patients had severe angina (Canadian Cardiovascular Society class \geq III), and over half had previous MI. In 79% of patients, the estimated occlusion age was >3 months. The angiographic and procedural variables are displayed in Table 2. A total of 91 lesions were treated. Two patients had a total occlusion of both the left anterior descending coronary artery and the right coronary artery with controlateral collateral flow. Of all CTOs, 51% were in the left anterior descending coronary artery distribution, with 34% and 15% in the right coronary artery and the

Table 2. Angiographic and Procedural Variables of 91 Chronic Total Coronary Artery Occlusions

Lesion location	
LAD	46 (51)
LCx	14 (15)
RCA	31 (34)
Abrupt morphology	55 (60)
Bridging collateral vessels	16 (17)
Calcification on fluoroscopy	19 (21)
Functional occlusion (TIMI flow grade 1)	25 (27)
Occlusion length (mm)	15.4 ± 9.4
Procedural dissection	31 (34)
Multiple stents	41 (45)
Reference diameter (mm)	
Baseline	3.12 ± 0.11
After stenting	3.11 ± 0.21
MLD after stenting (mm)	2.96 ± 0.26
DS after stenting (%)	13 ± 10
Nominal stent size (mm)	3.40 ± 0.35
Stent/vessel diameter ratio	1.09 ± 0.14
Final stent balloon pressure (atm)	11.9 ± 1.6

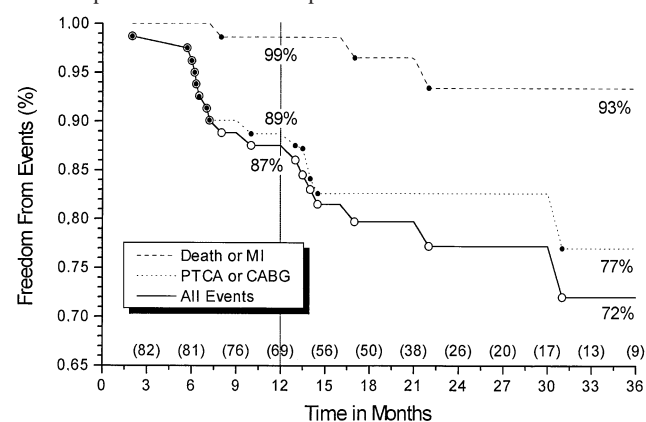
Data are presented as mean value ± SD or number (%) of lesions. DS = diameter stenosis; LAD = left anterior descending coronary artery; LCx = left circumflex coronary artery; MLD = minimal lumen diameter; RCA = right coronary artery; TIMI = Thrombolysis In Myocardial Infarction.

left circumflex artery, respectively. Functional occlusions were present in 27% of patients. The average length of occlusion was 15.4 ± 9.4 mm (median 16, range 4 to 47). A total of 148 Wiktor stents were implanted. Multiple stents were implanted in 41 lesions (45%): 4 stents in 3 lesions, 3 stents in 10 and 2 stents in 28. The mean number of stents per lesion was 1.6. The final minimal lumen diameter after stenting was 2.96 ± 0.26 mm, with a percent residual stenosis of 13 ± 10%. The average nominal stent size was 3.40 ± 0.35 mm. The nominal stent size to vessel diameter ratio was 1.09 ± 0.14 (median 1.0, range 0.5 to 1.5). The mean final stent balloon-inflation pressure was 11.9 ± 1.6 atm.

Intraprocedural and short-term outcome. Of 89 patients, stent implantation procedure was successfully performed in 87 (98%). In one patient stenting failed to cover a distal dissection that extended outside the length of the stenosis. This patient developed an angiographically documented acute stent occlusion 16 h after the intervention, which was associated with a Q wave MI, and subsequently underwent emergency CABG. In the other patient, the stent was positioned in a left circumflex artery but not at the site of the target lesion, which could not be successfully crossed because of vessel tortuosity despite satisfactory dilation. There were no instances of stent embolization or aborted attempts at stent delivery. No death or cerebrovascular complication occurred during the hospital stay. Short-term clinical follow-up was obtained in all patients at 1 month of intervention. During that interval, major bleeding events requiring blood transfusion occurred in 3 patients (3%): gastrointestinal bleeding in two patients and macroscopic hematuria in one patient. Vascular access-site complications requiring surgical vascular repair developed in one

patient (1%) who showed a pseudoaneurysm on color flow Doppler ultrasonography. Subacute stent thrombosis occurred in five patients (6%) on days 4, 8, 11, 14 and 23. Two of these patients had a nonfatal Q wave MI, one had a non-Q wave MI and the remaining two complained of sudden onset of angina. All patients underwent revascularization: PTCA in four patients and CABG in one. Remarkably, these five patients were treated with warfarin, which had been discontinued before SST in one patient (20%) because of bleeding complications. No case of SST occurred in patients treated with ticlopidine and aspirin or in patients with multiple stents.

Long-term follow-up. Of 82 patients with procedural success and without SST, long-term clinical follow-up was achieved in 100% at a mean time interval of 19 ± 12 months (range 2 to 44). Cardiac events occurred in 19 patients (23%). There was one death (1%) at 8 months due to congestive heart failure. Two patients (2%) had a nonfatal Q wave MI at 17 and 22 months, associated with in-stent restenosis in one and reocclusion in the other. These two patients underwent PTCA and CABG, respectively. Four patients developed unstable angina, due to in-stent restenosis in three and reocclusion in one. Two of these patients underwent CABG and two underwent PTCA. Ten patients underwent stented vessel PTCA for stable angina, due to restenosis at the stent site in nine patients and reocclusion in one. Two further patients with stable angina needed PTCA for new lesions in other vessels. The overall incidence of stented vessel revascularization was 19% (n = 16). The Kaplan-Meier event-free survival curves, including cardiac death, MI and stented vessel revascularization, are shown in Figure 1. Events exclude those precipitated by other vessels in patients with proven stent patency. The overall event-free survival rate was 87% at 1 year and subsequently declined to 72%. Referral for repeat PTCA or CABG tended to take place in the first 10 months after the procedure, with very little need for revascularization thereafter. The 13 patients who had repeat PTCA of the stented vessel remained asymptomatic at a mean of 17 ± 6 months after PTCA, with no further events, except for one patient who died of documented bronchial

Figure 1. Freedom from death, MI and repeat stent vessel revascularization after Wiktor stent implantation in CTO. Numbers in parentheses represent the number of patients at risk at each time interval.

carcinoma. Angiographic follow-up was accomplished at a mean of 6 ± 3 months (range 2 to 11) after the intervention. Control angiography was achieved in 76 (93%) of the 82 patients, as five asymptomatic patients declined the study and one died. Quantitative angiographic analysis was performed in 76 lesions of 76 patients. Measurements of nonoccluded segments documented a late lumen loss of 0.98 ± 0.81 mm and a loss index of 0.42 ± 0.38 . Restenosis was found in 24 patients (32%) and 24 lesions (32%), including 3 reocclusions (4%). Restenosis was observed in 18 of 35 lesions with multiple stents and in 6 of 41 lesions with a single stent. Thus, the multiple stent restenosis rate was 51%, significantly higher than the 15% rate for single stent ($p = 0.001$). Of the 24 patients with restenosis, 8 (33%) were asymptomatic and continued to receive medical therapy owing to the absence of demonstrable myocardial ischemia. A comparison of patients grouped according to the occurrence of restenosis at follow-up angiography is shown in Tables 3 and 4. No significant difference was seen with regard to clinical variables, except for a greater use of warfarin in the group with restenosis (71% vs. 40%, $p = 0.02$). As for angiographic and procedural variables, patients with restenosis had a significantly higher occlusion length (27.2 ± 6.3 mm vs. 13.2 ± 5.1 mm, $p < 0.005$) and frequency of multiple stents (75% vs. 33%, $p < 0.005$). The left anterior descending coronary artery was more often stented in patients with restenosis (63% vs. 37%, $p = 0.06$).

Logistic regression analysis. Among the clinical, angiographic and procedural variables examined (Table 1 and 2), the single positive predictor of SST by univariate analysis was warfarin therapy (chi-square 6.63, logistic regression coefficient [beta] 25.58, $p = 0.009$). A significant negative correlation of SST with either multiple stents (chi-square 5.52, beta -23.13, $p = 0.01$) or final minimal lumen diameter after stenting (chi-square 3.99, beta -4.06, $p = 0.04$) was also observed. However, when these variables were entered into multiple logistic regression analysis, no specific clinical feature

Table 3. Clinical Variables of Patients Grouped According to the Occurrence of Restenosis

	With Restenosis (n = 24)	Without Restenosis (n = 52)	p Value
Age (yr)	57 ± 8	58 ± 11	NS
Male gender	17 (71)	41 (79)	NS
Hypertension	9 (37)	17 (33)	NS
Cholesterol >200 mg/dl	8 (33)	13 (25)	NS
Diabetes mellitus	7 (29)	14 (27)	NS
Cigarette smoking	13 (54)	27 (52)	NS
CCS angina class ≥III	16 (67)	34 (65)	NS
Previous MI	14 (58)	30 (58)	NS
LVEF (%)	57 ± 11	56 ± 9	NS
Multivessel disease	13 (54)	27 (52)	NS
Occlusion >3 mo	19 (79)	39 (75)	NS
Warfarin therapy	17 (71)	21 (40)	0.02

Data are presented as mean value ± SD or number (%) of patients. Abbreviations as in Table 1.

Table 4. Angiographic and Procedural Variables in Patients Grouped According to the Occurrence of Restenosis

	With Restenosis (n = 24)	Without Restenosis (n = 52)	p Value
Stented vessel			
LAD	15 (63)	19 (37)	0.06
LCx	2 (8)	11 (21)	NS
RCA	7 (29)	22 (42)	NS
Abrupt morphology	14 (58)	31 (60)	NS
Bridging collateral vessels	4 (17)	8 (15)	NS
Calcification on fluoroscopy	5 (21)	10 (19)	NS
Functional occlusion (TIMI flow grade 1)	6 (25)	12 (23)	NS
Occlusion length (mm)	27.2 ± 6.3	13.2 ± 5.1	<0.005
Procedural dissection	9 (37)	17 (33)	NS
Multiple stents	18 (75)	17 (33)	<0.005
Reference diameter (mm)			
Baseline	3.12 ± 0.23	3.10 ± 0.33	NS
After stenting	3.10 ± 0.21	3.09 ± 0.25	NS
Follow-up	3.14 ± 0.20	3.12 ± 0.24	NS
MLD (mm)			
After stenting	2.95 ± 0.25	2.94 ± 0.24	NS
Follow-up	0.96 ± 0.33	1.99 ± 0.31	<0.005
DS (%)			
After stenting	12 ± 10	13 ± 10	NS
Follow-up	68 ± 17	27 ± 12	<0.005
Nominal stent size (mm)	3.40 ± 0.37	3.40 ± 0.36	NS
Stent/vessel diameter ratio	1.08 ± 0.15	1.09 ± 0.13	NS
Final stent balloon pressure (atm)	11.8 ± 0.8	11.9 ± 0.9	NS
Late lumen loss (mm)	1.99 ± 0.30	0.95 ± 0.32	<0.005
Loss index	0.67 ± 0.38	0.32 ± 0.39	<0.005

Data are presented as mean value ± SD or number (%) of patients. Abbreviations as in Tables 1 and 2.

or angiographic and procedural aspect was found to significantly explain the occurrence of SST. Significant correlates of restenosis are presented in Table 5. The final multivariate model (chi-square 31.71, $p < 0.00001$) included two of these variables. The strongest predictor of restenosis was multiple stent implantation (adjusted OR 27.67, 95% CI 4.25 to 79.95, $p = 0.0008$); an independent association was noted also with the length of the occlusion (adjusted OR 1.23, 95% CI 1.09 to 1.39, $p = 0.001$).

Discussion

This study presents the first multicenter experience with a coil stent for treatment of CTOs in the largest series of patients reported to date. Our results demonstrate that intracoronary Wiktor stent insertion can be safely and effectively performed after successful recanalization of CTO and is associated with a restenosis rate of 32% and very favorable long-term follow-up findings.

Success of the intervention. Our procedural success rate and immediate angiographic outcome match those achieved with the Palmaz-Schatz stent and the Wallstent for treatment of CTOs (3-7). The high delivery success rate and safety may

Table 5. Significant Correlates of Restenosis by Logistic Regression Analysis

	Univariate Analysis			Multivariate Analysis		
	Chi-Square	Beta-Coeff	p Value	Adjusted OR	95% CI	p Value
Warfarin therapy	6.23	1.27	0.018	—	—	—
Stented LAD	4.48	1.06	0.040	—	—	—
Occlusion length	10.02	0.10	0.003	1.23	1.09–1.39	0.001
Multiple stents	12.16	1.82	0.001	27.67	4.25–79.95	0.0008

Beta-Coeff = logistic regression coefficient; CI = confidence interval; LAD = left anterior descending coronary artery; OR = odds ratio (adjusted for other variables in model).

be explained by the low profile and longitudinal flexibility of the Wiktor stent, which allow more natural bending and tortuosity, factors that may be more favorable to dynamic coronary flow. Correct positioning during fluoroscopy may be easier with this tantalum stent in contrast to the scarcely visible stainless-steel devices. Radiopacity facilitates deployment of multiple stents exactly end to end with or without overlap for the complete coverage of long coronary lesions and dissections. Because of its design, the Wiktor stent has been hypothesized to have lower radial strength than other devices with a more rigid and stiff mesh architecture. However, *in vitro* data indicate that vascular support properties are not different for some flexible coils and slotted tube stents (13). The Wiktor stent, more recently tested by using the same *in vitro* model, has shown a resistance to circumferential collapsing pressure equivalent to that of the higher mass Gianturco-Roubin Flex-Stent and even greater than the rigid Palmaz-Schatz stent (Kirk N. Garratt, personal communication). Accordingly, experimental and clinical studies clearly indicate that the Wiktor stent effectively scaffolds the instrumented vessel, with only minimal elastic recoil, which does not contribute to late lumen renarrowing or restenosis (11,14–16). In agreement with these observations, coronary intervention with the Palmaz-Schatz stent and Wiktor stent have demonstrated comparable immediate and long-term angiographic benefits (17,18).

Short-term outcome. The incidence of SST (6%), vascular access-site complications (2%) and major bleeding events (3%) observed in the present study were lower than those obtained with the Wiktor stent in bailout situations or restenotic lesions (10–12). Chronic total coronary artery occlusions are a well recognized thrombotic milieu, as mural thrombosis is detected by angiography in most cases before and after PTCA (19). The acceptable thrombotic occlusion rate in the present study confirms the recent observation that elective coronary stenting is an effective therapeutic strategy even for patients with thrombus-laden lesions (20). The favorable short-term results of the current study compare well with those obtained with the Palmaz-Schatz stent in CTOs (3–6). Despite the use of a slotted tube stent, these previous studies are similar to ours in that neither high pressure postdilation inflations nor systematic intracoronary ultrasound was utilized. However, in the present study, a substantial proportion of patients were managed with aspirin plus ticlopidine, a regimen that has never been tested previously in patients with stented

CTOs. Notably, all of the patients with SST in our series were receiving classic oral anticoagulation, which could favor platelet activation and subsequent thrombosis (21). Despite a significant univariate association between warfarin therapy and SST in our study, the lack of evidence in favor of an independent relation may be due to the use of multiple regression analysis with a low event rate. Nevertheless, our data are consistent with recently published studies demonstrating that patients who receive slotted tube or coil stents with optimal angiographic results without intravascular ultrasound guidance may be managed safely with a combination of aspirin and ticlopidine without anticoagulation (22–25). Results of the Full Anticoagulation Versus Aspirin-Ticlopidine (FANTASTIC) randomized trial are also awaited to assess the risk/benefit ratio of anticoagulation and to define optimal pharmacologic treatment after coronary Wiktor stenting (26).

The adverse impact of coronary dissection on the risk of SST after coil stent deployment has been documented previously (27). However, our study has not shown a specific statistical association between procedural dissection and SST. This may be attributed in part to multiple stent implantation, which would allow the entire diseased segment to be adequately covered and seems to have a protective effect with respect to the occurrence of SST (negative correlation with the event). Although there have been concerns that increased exposure of metal may be more thrombogenic, several investigators have concluded that multiple stents do not enhance the risk of SST when they are carefully deployed without excessive overlapping (28–30). The loose interdigitating wire design of the Wiktor stent accounts for <10% of the total vessel surface covered, which could limit its thrombotic potential (14). However, the issue of a possible lower SST and vascular injury with a specific design or metal is an interesting aspect that so far has only been addressed in experimental models (31,32).

Long-term outcome. In this study, the long-term clinical outcome, restenosis rate and predictors of restenosis of patients undergoing Wiktor stent implantation in CTOs are presented. The restenosis and reocclusion rates in our study compare favorably with those obtained with the Palmaz-Schatz stent and Wallstent (3–7). The clinical outcome was also satisfactory, with excellent overall survival and low event rates. Over 3 years, only three patients (4%) required CABG. In addition, the 13 patients who underwent repeat PTCA for

in-stent restenosis have been free of clinical recurrence at a mean follow-up of 17 ± 6 months. Thus, coronary surgery can be avoided in most patients whose totally occluded vessels are successfully stented. It is also interesting to note that 33% of patients who met the angiographic criteria for restenosis were asymptomatic and had no signs of inducible myocardial ischemia. These findings support the conclusion that borderline lumen stent narrowing (60% to 70%) by quantitative coronary angiography correlates poorly with both clinical symptoms and prognosis (33). To reduce the likelihood of long-term failure of stenting CTOs and possibly improve technical approaches for managing such lesions, factors that predict the occurrence of restenosis must be defined. According to our results, a long occlusive lesion may confer a higher risk of restenosis after stenting. This is in keeping with recent preliminary data that outline the influence of lesion length and complexity on late angiographic outcome and restenotic process after successful coronary stent implantation (34,35). A plausible explanation of this finding may be a significant residual plaque burden, resulting from more severe and diffuse underlying atherosclerosis, which is underestimated by angiographic lumen measurements and may itself be a determinant of restenosis. In a previous study by Goldberg et al. (4), the presence of a moderate to severe dissection after Palmaz-Schatz stenting of CTOs was the only significant variable associated with restenosis, but multiple stent implantation was not considered among the angiographic and procedural predictors. Because multiple stents were liberally used in our study for complete coverage of dissections and long lesions, the relation between dissection and restenosis may have been concealed. In our experience, the implantation of multiple contiguous stents showed a very strong independent association with restenosis. As already observed in the early stent era, greater metal density and repeat stent-on-stent trauma might impair passivation, promote thrombus formation and myointimal regrowth and thereby increase the risk of restenosis (36). Despite major advances in deployment techniques, our present observations as well as very recent preliminary data from patients with elective or nonelective coronary stenting (37,38) confirm the relatively poor long-term outcome of multiple stents. However, further studies are needed to clarify whether the use of multiple stents yields the same long-term benefits demonstrated with single stents.

Study limitations. This study did not compare coronary stenting with conventional PTCA of CTOs. However, considering the high restenosis rate of 44% to 77%, including reocclusion in 14% to 40% of patients, and a reintervention rate >50% observed with PTCA alone (1,5-7), the addition of an angioplasty control group would not have been cost-effective and could have only confirmed the advantage of stenting for this difficult clinical condition. Intracoronary ultrasound and high pressure balloon inflation to ensure optimal stent expansion have been reported to improve the immediate clinical outcome and reduce the frequency of SST in patients receiving a Palmaz-Schatz stent (39). Because concerns exist regarding crossing coil stents with current intravascular ultra-

sound devices and poorly profiled high pressure balloon catheters (40), we did not use intravascular ultrasound and peak balloon-inflation pressures were not particularly high. However, recent preliminary data suggest that high pressure balloon dilation may increase late lumen loss after coronary stenting (41,42). Despite implanting the stent in CTO, in which one would expect a high late loss, we obtained a relatively low loss index. This finding may testify to the benefit of moderate pressure stent deployment, achieving a low residual stenosis without creating excessive vessel wall injury. In addition, preliminary data from a recently completed randomized study with the Wiktor stent, in which routine high pressure balloon inflations (≥ 14 atm) were compared with "standard" pressure inflations (8 atm) revealed that high pressure inflations increased lumen dimensions (as assessed by intravascular ultrasonography) but did not improve the immediate and 6-month clinical or angiographic outcomes, which were excellent in both groups (43,44).

Conclusions. Our study points out the favorable short- and long-term clinical and angiographic outcomes with the Wiktor stent for treatment of CTOs. The high incidence of SST in the warfarin group has decreased the rate of short-term successful results, which might have been still better with the current, well admitted management strategy (i.e., ticlopidine plus aspirin). Although the use of multiple stents may increase the risk of restenosis, this is offset by the low rate of SST owing to the ability to completely cover coronary dissections. A second generation of Wiktor stents with a short wave design and heparin coating and the novel polymer-coated eluting Wiktor stent (45) will probably help reduce SST and prevent restenosis. Further refinements and improvements in stent implantation techniques for CTOs are needed to reduce restenosis in patients with long lesions. However, the long-term clinical results were favorable because most patients with restenosis were successfully treated with repeat PTCA. These encouraging findings provide evidence in support of elective Wiktor stent implantation in CTO as a cost-effective procedure.

We thank Kirk N. Garratt, MD, of the Mayo Clinic and Foundation, Rochester, Minnesota, for providing the data from his work group, and Willard W. Hennemann, PhD, of Medtronic Interventional Vascular, Kerkrade, The Netherlands, for useful comments.

References

1. Puma JA, Sketch MH, Tchong JE, et al. Percutaneous revascularization of chronic coronary occlusions: an overview. *J Am Coll Cardiol* 1995;26:1-11.
2. Kinoshita I, Katoh O, Nariyama J, et al. Coronary angioplasty of chronic total occlusions with bridging collateral vessels: immediate and follow-up outcome from a large single-center experience. *J Am Coll Cardiol* 1995;26:409-15.
3. Medina A, Meliàn F, Suarez de Lezo J, et al. Effectiveness of coronary stenting for the treatment of chronic total occlusion in angina pectoris. *Am J Cardiol* 1994;73:1222-4.
4. Goldberg SL, Colombo A, Maiello L, Borriore M, Finci L, Almagor Y. Intracoronary stent insertion after balloon angioplasty of chronic total occlusions. *J Am Coll Cardiol* 1995;26:713-9.
5. Mori M, Kurogane H, Hayashi T, et al. Comparison of results of intracoro-

- nary implantation of the Palmaz-Schatz stent with conventional balloon angioplasty in chronic total coronary occlusion. *Am J Cardiol* 1996;78:985-9.
6. Sirnes PE, Golf S, Myreng Y, et al. Stenting In Chronic Coronary Occlusion (SICCO): a randomized, controlled trial of adding stent implantation after successful angioplasty. *J Am Coll Cardiol* 1996;28:1444-51.
 7. Ozaki Y, Violaris AG, Hamburger J, et al. Short- and long-term clinical and quantitative angiographic results with the new, less shortening Wallstent for vessel reconstruction in chronic total occlusion: a quantitative angiographic study. *J Am Coll Cardiol* 1996;28:354-60.
 8. Buchwald A, Unterberg C, Werner G, Voth E, Kreuger H, Wiegand V. Initial clinical results with the Wiktor stent: a new balloon expandable coronary stent. *Clin Cardiol* 1991;14:374-9.
 9. Vaishnav S, Aziz S, Layton C. Clinical experience with the Wiktor stent in native coronary arteries and coronary bypass grafts. *Br Heart J* 1994;72:288-93.
 10. Vrolix M, Piessens J. Usefulness of the Wiktor stent for treatment of threatened or acute closure complicating coronary angioplasty. *Am J Cardiol* 1994;73:737-41.
 11. de Jaegere PP, Serruys PW, Bertrand M, et al. Wiktor stent implantation in patients with restenosis following balloon angioplasty of a native coronary artery. *Am J Cardiol* 1992;69:598-602.
 12. Bertrand OF, Legrand V, Bilodeau L, Martinez CA, Kulbertus HE. Emergency coronary stenting with Wiktor stent—immediate and late results. *J Invas Cardiol* 1997;9:2-9.
 13. Grègoire J, Smith D, Ragheb A, et al. Effect of stent design and configuration on collapse resistance to external circumferential pressure [abstract]. *J Am Coll Cardiol* 1997;27 Suppl:414A.
 14. van der Giessen WJ, Serruys PW, van Beusekom HMM, et al. Coronary stenting with a new, radiopaque, balloon-expandable endoprosthesis in pigs. *Circulation* 1991;83:1788-98.
 15. Serruys P, De Jaegere P, Bertrand M, et al. Morphologic change in coronary artery stenosis with the Medtronic Wiktor stent: initial results from the core laboratory for quantitative angiography. *Cathet Cardiovasc Diagn* 1991;24:237-45.
 16. de Jaegere P, Serruys PW, van Es GA, et al. Recoil following Wiktor stent implantation for restenotic lesions of coronary arteries. *Cathet Cardiovasc Diagn* 1994;34:147-56.
 17. Eeckhout E, Goy JJ, Stauffer JC, Vogt P, Kappenberger L. Comparison of the Wallstent, Palmaz-Schatz stent and Wiktor stent late after intracoronary stenting. *Am J Cardiol* 1994;74:609-12.
 18. White CJ. Stent recoil: comparison of the Wiktor-GX coil and the Palmaz-Schatz tubular coronary stent. *Cathet Cardiovasc Diagn* 1997;41:1-3.
 19. Alfonso F, Goicolea J, Hernandez R, et al. Angioscopic findings during coronary angioplasty of coronary occlusions. *J Am Coll Cardiol* 1995;26:135-41.
 20. Alfonso F, Rodriguez P, Phillips P, et al. Clinical and angiographic implications of coronary stenting in thrombus containing lesions. *J Am Coll Cardiol* 1997;29:725-33.
 21. Gawaz M, Neumann FJ, Ott I, May A, Schömig A. Platelet activation and coronary stent implantation: effect of antithrombotic therapy. *Circulation* 1996;94:279-85.
 22. Schömig A, Meumann FJ, Kastrati A, et al. A randomized comparison of antiplatelet and anticoagulant therapy after placement of coronary artery stents. *N Engl J Med* 1996;334:1084-9.
 23. Karrison GJ, Morice MC, Benveniste E, et al. Intracoronary stent implantation without ultrasound guidance and with replacement of conventional anticoagulation by antiplatelet therapy. *Circulation* 1996;94:1519-27.
 24. Goods CM, Al-Shaibi KF, Yadav SS, et al. Utilization of the coronary balloon expandable coil stent without anticoagulation or intravascular ultrasound. *Circulation* 1996;93:1803-8.
 25. Park SV, Park SJ, Hong MK, et al. Coronary stenting (Cordis) without anticoagulation. *Am J Cardiol* 1997;79:901-4.
 26. Bertrand M, Legrand V, Boland J, et al. Full anticoagulation versus ticlopidine plus aspirin after stent implantation: a randomized multicenter European study: the FANTASTIC trial [abstract]. *Circulation* 1996;94 Suppl I:I-685.
 27. Agrawal SK, Ho DSW, Liu MW, et al. Predictors of thrombotic complications after placement of the flexible coil stent. *Am J Cardiol* 1994;73:1216-9.
 28. Nath CF, Muller DWM, Ellis SG, et al. Thrombosis of a flexible coil coronary stent: frequency, predictors and clinical outcome. *J Am Coll Cardiol* 1993;21:622-7.
 29. Colombo A, Goldberg SL, Almagor Y, Maiello L, Finci L. A novel strategy for stent deployment in the treatment of acute or threatened closure complicating balloon coronary angioplasty: use of short or standard (or both) single or multiple Palmaz-Schatz stents. *J Am Coll Cardiol* 1993;22:1887-91.
 30. Foley JB, Brown RIG, Penn IM. Thrombosis and restenosis after stenting in failed angioplasty: comparison with elective stenting. *Am Heart J* 1994;128:18-20.
 31. Rogers C, Edelman ER. Endovascular stent design dictates experimental restenosis and thrombosis. *Circulation* 1995;91:2995-3001.
 32. Sheth S, Litvach F, Dev V, Fishbein MC, Forrester JS, Eigler N. Subacute thrombosis and vascular injury resulting from slotted-tube nitinol and stainless steel stents in a rabbit carotid artery model. *Circulation* 1996;94:1733-40.
 33. Gordon PC, Friedrich SP, Piana RN, et al. Is 40% to 70% diameter narrowing at the site of previous stenting or directional coronary atherectomy clinically significant? *Am J Cardiol* 1994;74:26-32.
 34. Schühlen H, Hausleiter J, Elezi S, et al. Are ACC/AHA lesion characteristics predictive for late angiographic results after coronary stent placement? [abstract]. *J Am Coll Cardiol* 1997;29 Suppl:239A.
 35. Hamasaki N, Nosaka H, Kimura T, et al. Influence of lesion length on late angiographic outcome and restenotic process after successful stent implantation [abstract]. *J Am Coll Cardiol* 1997;29 Suppl:239A.
 36. Ellis SG, Savage M, Fischman D, et al. Restenosis after placement of Palmaz-Schatz stents in native coronary arteries. *Circulation* 1992;86:1836-44.
 37. Pulsipher MW, Baker WA, Sawchak SR, et al. Outcomes in patients treated with multiple coronary stents [abstract]. *Circulation* 1996;94 Suppl I:I-332.
 38. Aliabadi D, Bowers TR, Tilli FV, et al. Multiple stents increases target vessel revascularization rates [abstract]. *J Am Coll Cardiol* 1997;29 Suppl:276A.
 39. Colombo A, Hall P, Nakamura S, et al. Intracoronary stenting without anticoagulation accomplished with intravascular ultrasound guidance. *Circulation* 1995;91:1676-88.
 40. Nicosia A, van der Giessen WJ, Airiian SG, von Birgelen C, de Feyter PJ, Serruys PW. Is intravascular ultrasound after coronary stenting a safe procedure? Three cases of stent damage attributable to ICUS in a tantalum coil stent. *Cathet Cardiovasc Diagn* 1997;40:265-70.
 41. Fernández-Avilés F, Alonso JJ, Durán JM, et al. High pressure increases late loss after coronary stenting [abstract]. *J Am Coll Cardiol* 1997;27 Suppl:369A.
 42. Hoffmann R, Mintz GS, Mehran R, et al. Late tissue proliferation both within and surrounding Palmaz-Schatz stents is associated with procedural vessel wall injury [abstract]. *J Am Coll Cardiol* 1997;27 Suppl:397A.
 43. Yang P, Hassan A, Heyer G, et al. High-pressure post-dilatation of the Medtronic Wiktor stent: intravascular ultrasound and quantitative angiographic data from the Austrian Multicenter Trial [abstract]. *Circulation* 1996;94 Suppl I:I-207.
 44. Glogar D, Yang P, Hassan A, et al. Does high-pressure balloon post-dilatation improve long-term results of Wiktor coil stent? (Austrian Wiktor stent trial) [abstract]. *J Am Coll Cardiol* 1997;27 Suppl:313A.
 45. Lincoff AM, Furst JG, Ellis SG, Tuch RJ, Topol EJ. Sustained local delivery of dexamethasone by a novel intravascular eluting stent to prevent restenosis in the porcine coronary injury model. *J Am Coll Cardiol* 1997;29:808-16.