

Endovascular treatment of aortic pseudoaneurysm in Behçet disease

Chang-Wei Liu, MD,^a Wei Ye, MD,^a Bao Liu, MD,^a Rong Zeng, MD,^a Weiwei Wu, MD,^a and Michael D. Dake, MD,^b *Beijing, China; and Stanford, Calif*

Objective: This study evaluated the feasibility, efficacy, and outcome of endovascular therapy combined with immunosuppressive therapy for aortic pseudoaneurysms in patients with Behçet disease.

Methods: Between April 2002 and April 2008, 12 pseudoaneurysms (9 involving the intrarenal abdominal aorta, 1 at the suprarenal level, and 2 in the supraceliac aorta) in nine men and one woman with Behçet disease were evaluated at Peking Union Medical Center (PUMC). Three bifurcated stent grafts and seven tubular stent grafts, including two fenestrated stent grafts, were deployed. All 10 patients received immunosuppressive therapy after the implant procedure.

Results: All patients underwent successful endovascular therapy without major complications during the 30 days immediately after the procedure. One patient with two aneurysms had treatment of only the larger infrarenal symptomatic aneurysm, but the smaller suprarenal pseudoaneurysm was not addressed because of its proximity to mesenteric branches. During a mean follow-up of 25.8 months (range, 6-50 months), nine aneurysms resolved completely in eight patients. The only untreated aneurysm, which coexisted with a treated lesion, remained stable under imaging observation. Three aneurysms recurred in two patients. At 6 months, one patient presented with a new aneurysm at the femoral artery access site for stent graft introduction and another formed at the proximal margin of the stent graft. Despite medical advice, he had stopped immunotherapy. He died from aneurysm rupture 8 months after stent deployment. Another patient with recurrent aneurysmal disease at the distal margin of the primary stent was successfully treated with an additional stent graft. These two were the only patients who did not adhere to taking immunosuppressant medicine after discharge.

Conclusion: Endovascular stent graft placement combined with immunosuppressive treatment for aortic pseudoaneurysms in Behçet disease is a feasible and effective management option. Long-term immunosuppressive therapy after endovascular repair is important to limit pseudoaneurysm recurrence. (*J Vasc Surg* 2009;50:1025-30.)

Arterial involvement in Behçet disease (BD) is not commonly seen, with several studies documenting prevalences of 2.2% to 18% of patients and aortic lesions in 1.5% to 2.7%.¹⁻⁴ Aortic involvement is one of the most severe manifestations and is associated with a much higher mortality than that observed in BD patients without aortic disease.¹⁻⁴ Open surgical repair is recommended in most patients, but postoperative complications, such as graft occlusions or anastomotic pseudoaneurysm formation, are frequent.⁵⁻⁷

Initial reports suggest that endovascular stent grafting may provide an alternative treatment option in these complicated cases, although the encouraging results are limited to only short-term follow-up.⁸⁻¹⁰ Nitecki et al¹¹ reported that endovascular treatment offers lower combined mortality and morbidity (especially in cases of anastomotic pseudoaneurysms) than open surgery. In this article, we

present our experience with endovascular stent graft treatment of aortic pseudoaneurysm in 10 patients with BD.

MATERIALS AND METHODS

Between April 2002 and April 2008, nine men and one woman with BD underwent evaluation and endovascular treatment of 12 aortic pseudoaneurysms. Their median age was 35.5 years (range, 24-54 years). The diagnosis of BD was confirmed using the criteria detailed by the International Study Group for Behçet's Disease.¹² This required documentation of recurrent oral ulceration in association with at least two of the following: characteristic ocular lesions, characteristic skin lesions, genital ulceration, and positive pathergy test.

Patient clinical data are summarized in Table I. The pseudoaneurysms were diagnosed with computed tomography angiography (CTA) or angiography. Nine patients had 11 spontaneous, nontraumatic pseudoaneurysms. One patient's pseudoaneurysm was associated with penetration of the aorta by legs of an inferior vena cava filter. The most frequent symptoms were abdominal and back pain (8 of 10 patients). Two patients with chronic aortic lesions (patients 1 and 8) did not experience pain before undergoing the endovascular procedure.

Immunosuppressive treatment. Three patients (patients 3, 5, and 6), who had symptomatic pseudoaneurysms and imaging evidence of life-threatening aortic rupture, received intravenous glucocorticoids (hydrocortisone, 200 mg/d), and cyclophosphamide (200 mg/d) was com-

From the Department of Vascular Surgery, Peking Union Medical College Hospital, Chinese Academy of Medical Science and Peking Union Medical College, Beijing^a; and the Department of Cardiothoracic Surgery, Stanford University School of Medicine, Stanford.^b

Competition of interest: Dr Dake is a member of the Scientific Advisory Board of W. L. Gore and Associates, and Medtronic Inc, and receives a consulting fee for work in this capacity.

Reprint requests: Michael D. Dake, MD, Stanford University Medical Center, Falk Cardiovascular Research Center, Department of Cardiothoracic Surgery, 300 Pasteur Dr, 2nd Floor, Stanford, CA 94305-5407 (e-mail: mddake@stanford.edu).

0741-5214/\$36.00

Copyright © 2009 by the Society for Vascular Surgery.

doi:10.1016/j.jvs.2009.06.009

Table I. Patient demographics, clinical features, details of stent grafting, and follow-up data

Patient	Sex	Age Y	Aortic manifestation	Pseudoaneurysm details		
				Location	Max diameter, mm	Interval between diagnosis and treatment
1	M	26	2 pseudoaneurysms	1 juxtarenal; 1 infrarenal	22	1 y
2	M	54	Pseudoaneurysm	Juxtarenal	16	3 d
3	M	24	Ruptured pseudoaneurysm	Bifurcation	28	12 h
4	M	35	Pseudoaneurysm	Infrarenal	24	3 wk
5	M	53	Ruptured pseudoaneurysm	Juxtaceliac artery	36	4 h
6	M	46	Ruptured pseudoaneurysm	Infrarenal	142	3 h
7	M	27	Pseudoaneurysm	Infrarenal	20	1 wk
8	M	36	Pseudoaneurysm	Bifurcation	26	1 y
9	M	49	2 pseudoaneurysms	1 Suprarenal; 1 infrarenal	24	2 wk
10	F	35	Pseudoaneurysm	Supraceliac	18	2 wk

AMI, Acute myocardial infarction; CIA, common iliac artery; CRP, C-reactive protein; DVT, deep vein thrombosis; ESR, erythrocyte sedimentation rate; F, female; ICA, internal carotid artery; M, male; PFA, profunda femoral artery.

^aNormal ESR value <20 mm/h.

^bNormal CRP reference range, 0 to 8.0 mg/L.

menced once the diagnosis was made, immediately before endovascular therapy. At the time of the procedure, their erythrocyte sedimentation rates (ESR) were 33 to 62 mm/h (normal reference range, 8-15 mm/h), and C-reactive protein (CRP) values were 40 to 56 mg/L (normal, 0.1-0.5 mg/L).

Five symptomatic patients (patients 2, 4, 7, 9, and 10) with nonruptured pseudoaneurysms were administered immunosuppressive treatment with oral prednisone (60 mg/d) combined with cyclophosphamide (200 mg/d) for 1 to 3 weeks until the ESR and CRP values were within the normal range. Once their inflammatory markers normalized, they underwent endovascular stent graft implantation. Patients 1 and 8 received oral immunosuppressive treatment with prednisone (5 to 10 mg/d) for 1 year before stent graft placement. At the time of the procedures, their respective ESR and CRP values were 3 and 6 mm/h and 0.3 and 0.9 mg/L.

After the endograft procedure, intravenous hydrocortisone (200 mg/d) combined with cyclophosphamide (200 mg/d) was continued for at least 3 days. The eight acute and subacute patients then began receiving oral prednisone (60 mg/d) and cyclophosphamide (200 mg/qod). This drug regimen was tapered intermittently, adjusted in conjunction with the individual patient's response and guidelines provided by the consulting rheumatologists. All patients were advised to maintain immunosuppressive therapy for at least 2 years.

Endovascular stent grafting. Endovascular stent grafts were deployed successfully in all patients. The time from diagnosis to treatment was between 3 hours and 1 year. Three patients underwent stent graft implantation within hours of the diagnosis, five between 1 and 3 weeks of the diagnosis, and the two chronic asymptomatic patients underwent the endograft procedure at 1 year after long-term immunosuppressive drug therapy.

The choice of the stent graft design was based on the individual patient's anatomy, especially the proximity of the lesion(s) to aortic branch vessels. Three bifurcated stent grafts were deployed for abdominal aortic aneurysms adjacent to the aortic bifurcation. Seven tubular stent grafts were implanted to repair pseudoaneurysms with sufficient proximal and distal aortic neck segments of healthy vessel appropriate for anchoring the graft. In this group, two stent grafts were deployed in the supraceliac aorta, and five stent grafts were placed in the infrarenal aorta. Two fenestrated grafts were also used. The devices did not have barbs, hooks, or other anchors to provide supplemental fixation, and in three instances, a terminal bare stent body was removed to limit the potential of injury to a diseased aorta.

Of note, there were three special cases in our series. One patient with two aneurysms was treated with a tubular stent graft for the larger symptomatic infrarenal aneurysm; however, another smaller suprarenal lesion was conservatively managed because it was close to visceral branches. Two patients with juxtarenal aneurysms were treated successfully using fenestrated stent grafts. The graft fenestrations included one with a scallop (Fig 1) and one with a small window and scallop (Fig 2). These unique custom-fabricated grafts were created with the use of Hercules-T stent grafts, which combine a nitinol stent endoskeleton with polytetrafluoroethylene graft material (MicroPort Medical, Inc., Shanghai, China) and manual shearing to fashion the openings. The locations of the fenestrations were preoperatively planned with the use of multiplanar CTA imaging and created by the surgeon during the operation to accommodate the target renal ostia.

RESULTS

Ten patients underwent stent graft placement for abdominal aortic pseudoaneurysms. The signs and symptoms that led to the diagnosis of BD included recurrent oral ulcer

Table I. Continued.

Other vascular involvement	Inflammatory markers		Stent graft design	Adjunctive alteration of device	Aneurysm recurrence	Follow-up mon	Patient status
	ESR, mm/h ^a	CRP, mg/L ^b					
Left lower limb DVT	3	1.2	Tube	Custom fenestration		44	Alive
	29	18	Tube			47	Alive
History of AMI, left ICA aneurysm	62	56	Bifurcated	Remove bare stent cuff	6 mon 4 mon	8	Died
	21	24	Tube			16	Alive
1 more aneurysm on right CIA, 1 aneurysm on left PFA	45	55	Tube	Remove bare stent cuff		18	Alive
	33	40	Bifurcated			50	Alive
Right lower limb DVT	68	89	Tube	Remove bare stent cuff		36	Alive
History of AMI, left lower limb DVT	6	2.5	Bifurcated	Suprarenal aneurysm; being observed with follow-up imaging		25	Alive
	27	5.7	Tube			6	Alive
	18	6.7	Tube			8	Alive

(100%), skin lesion (80%), recurrent genital ulcer (70%), positive pathergy test (40%), and ocular lesion (20%). Elevations of ESR and CRP values were observed in all but the two chronic patients who had received immunosuppressant therapy for 1 year. ESR and CRP values for the patients are detailed in Table I.

Ten procedures were performed for the 10 patients. All the stent graft deployments were successful, including three bifurcated stent grafts, five tubular stent grafts, and two tubular fenestration stent grafts. All the stent grafts were introduced through surgical cutdown and femoral arteriotomy. All of the procedures were performed <150 minutes, with blood loss of <50 mL uniformly.

No endoleaks were identified on completion aortography. No balloon dilation or molding of the stent graft after deployment was performed. Primary closure of the femoral artery without the use of a patch was used in all cases; percutaneous access or closure of the femoral artery was not used. Three urgent procedures were performed for life-threatening ruptured pseudoaneurysms. There were no groin wound infections, stent occlusions, or deaths ≤30 days after the procedure.

After hospital discharge, patient follow-up was 100% for a mean of 25.8 months (range, 6-50 months). Recurrent pseudoaneurysms were documented in two patients. Patient 3 discontinued immunotherapy after hospital discharge, against medical recommendations and without knowledge of his physicians. At 6 months after the procedure, a new pseudoaneurysm at the femoral artery access site and another pseudoaneurysm at the proximal edge of the stent graft were diagnosed. He presented as an emergency at another hospital 8 months after the initial procedure and died of rupture of the aortic pseudoaneurysm. In the other patient, a second stent graft was deployed 6 months after the initial procedure to treat recurrence of the

primary aneurysm that occurred after he refused to maintain immunosuppressive therapy. In the patient who died, values for CRP and ESR were not obtained at the time of the recurrent aortic pseudoaneurysm rupture. For the other patient with a pseudoaneurysm, ESR was 21 mm/h and CRP was 5.3 mg/L. This patient underwent a successful reintervention and was maintained on immunosuppressive therapy for >1 year after the second procedure.

The overall survival rate is 90% in our series. The complication-free survival rate is 80% (8 of 10). The patient with the untreated suprarenal pseudoaneurysm continues to undergo CT imaging surveillance without a change in the aneurysm size, 6 months after hospital discharge.

DISCUSSION

BD is an autoimmune disorder that involves multiple organs. The prevalence of BD has a marked geographic variation. The United Kingdom has an estimated 2000 BD, but the prevalence is much higher in Japan at 10 per 100,000 and in Turkey at 8 to 38 per 100,000 population.¹³ The prevalence in China is unknown.

Aortic involvement occurs in approximately one-third of BD patients with vascular disease,³ and it is more common in men. The initial presentation of the disease usually occurs between age 20 and 30 years. Vasculitis is believed to be the main pathophysiologic lesion underlying vascular disease in BD. Venous thrombosis, arterial thrombosis, and arterial aneurysm are the most common manifestation of the inflammatory vascular component of BD. Arterial involvement usually indicates a poor prognosis for patients with BD and accounts for most of the deaths.^{1,4}

Aortic pseudoaneurysm is the most lethal lesion in BD. The incidence of rupture and death is uncertain, but these lesions are generally considered high risk. Surgical treatment is deemed essential; however, aortic pseudoaneurysm

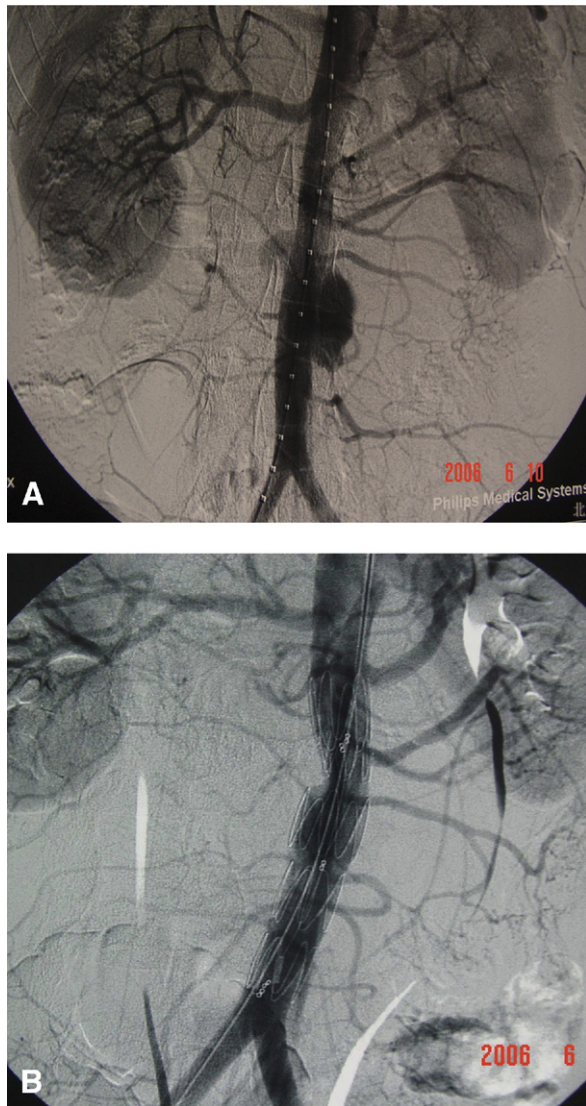


Fig 1. Aortic pseudoaneurysm involving the infrarenal segment in patient 1. **A**, Aortogram before stent placement displays an irregular, multilobed lesion adjacent to the accessory left renal artery. **B**, Completion aortogram after stent graft deployment confirms exclusion with preserved perfusion of the left accessory renal artery to the lower pole of the kidney.

in BD is regarded as a complicated and challenging pathology by vascular surgeons because of the technical operative difficulties and frequent recurrence. Several articles detail the complications of open surgical treatment for aortic pseudoaneurysm.^{5,6,11,14-16} Aneurysm-related mortality with surgery is 10% to 30%, and recurrent false aneurysm at an anastomotic site develops in 10% to 50% of patients. Graft occlusion or infection, as well as thromboembolic events, are also not uncommon (Table II).

Endovascular treatment is a recent innovation that may prove to be the treatment of choice in patients with major risk factors for open surgery. In 1998 Vasseur et al⁸ first

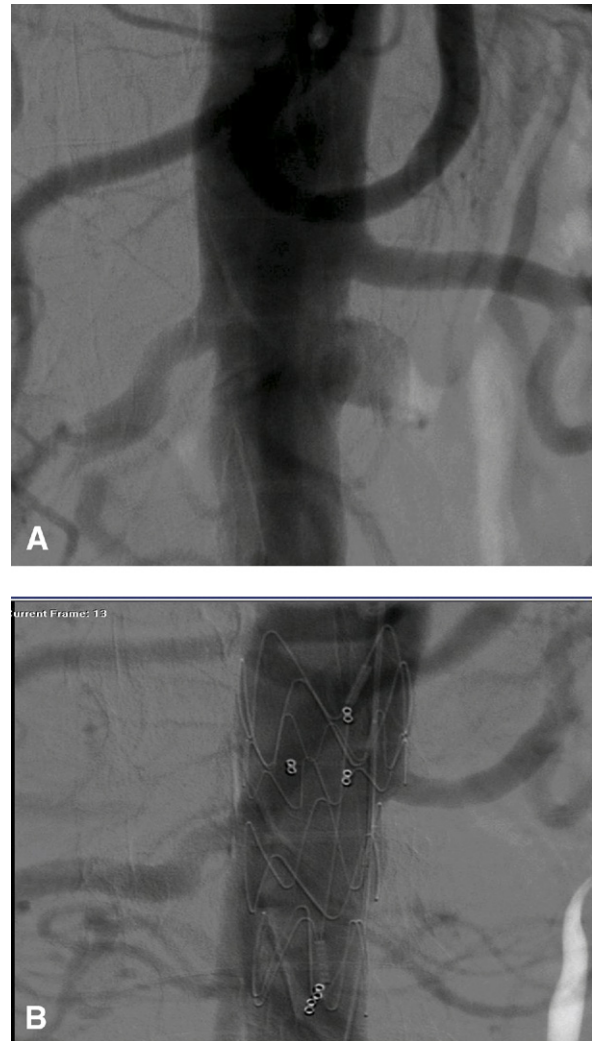


Fig 2. Juxtarenal pseudoaneurysm in patient 2. **A**, Aortogram shows eccentric, left-sided, saccular, pseudoaneurysm opposite the right renal artery and immediately distal to the left renal artery. **B**, Aortogram after fenestrated stent graft placement shows no opacification of the aneurysm and normal visualization of the renal arteries.

reported endovascular treatment of a BD patient with aortoiliac false aneurysms using a bifurcated stent graft. This showed that endovascular treatment could provide a feasible, less invasive alternative to surgery for patients with aortic pseudoaneurysm due to BD.

Since their initial description, other investigators have reported experience with endoluminal treatment in an attempt to eliminate the potential for aneurysm formation at anastomotic sites or to treat a recurrent aneurysm at an anastomotic site.^{11,17,18} To our knowledge, our series of 10 patients is the largest experience from a single center, and the outcomes strengthen the case for endoluminal treatment as an alternative to open surgical repair. Table II details the experience reported in the medical literature

Table II. Meta-analysis of published reports detailing open surgical and endovascular management of patients with Behçet disease and aneurysmal lesions

First author	Year	Cases no.	Surgical no.	Endovascular no.	Aneurysm-related death no. (%)	Recurrence no. (%)	Thrombosis no. (%)	Follow-up (Mean)
Okada ¹⁴	1997	8	14	...	1 (12.5)	1 (12.5)	0	6.8 y
Tüzün ¹⁵	1997	24	24	...	1 (4.2)	0 (0)	4 (16.7)	47.3 mon
Nitecki ¹¹	2004	3	3	...	1 (33.3)	0	1 (33.3)	4 y
Kalko ⁶	2005	16	19	...	0 (0)	3 (18.75)	1 (6.25)	17 mon
Iscan ¹⁶	2005	20	25	...	2 (10)	10 (50)	9 (45)	44 mon
Kwon ⁵	2008	12	21	...	2 (16.7)	6 (50)	0	45.4 mon
Park ¹⁷	2001	7	...	8	0 (0)	1 (14.3)	2 (28.6)	28 mon
Koo ¹⁸	2003	9	...	11	0 (0)	2 (22.2)	2 (22.2)	24.1 mon
Nitecki ¹¹	2004	2	...	2	0 (0)	0 (0)	0 (0)	33 mon

with a variety of open surgical and endovascular techniques for the management of vascular lesions associated with BD.

In our 10 patients, all endovascular stent grafts were deployed successfully, with complete exclusion of 11 pseudoaneurysms, including the two patients with juxtarenal aneurysms that required placement of fenestrated stent grafts. Fenestrated graft techniques have been described previously.¹⁹⁻²¹ Fenestrated graft procedures are complex and require experienced interventional skills as well as the ability to solve intraoperative complications with endovascular techniques.

We learned from our initial experience that it is critically important to determine before the procedure the desired position of the fenestration based on high-resolution CT imaging to accurately deploy the graft over the ostium of the target vessel during the operation. Because custom-made fenestrated stent grafts are currently unavailable in China, intraprocedural fenestration of the stent graft was performed by the interventionalists in all procedures.

One of the two patients in our series who presented with recurrent aneurysms died of aneurysm rupture. Aneurysm recurrence after repair is a major problem and difficult to avoid completely in BD. As a result, we believe immunosuppressant and anti-inflammatory medication should be maintained long-term to suppress vasculitis and prevent recurrent aneurysm after intervention in BD.

According to the 2008 European League Against Rheumatism (EULAR) recommendations for management of BD,²² there is no conclusive evidence to guide the definite management of major vessel disease in BD. These recommendations acknowledge that peripheral artery aneurysms carry a high risk of rupture and advise surgical repair accompanied by systemic immunosuppressives. Cyclophosphamide and corticosteroids are suggested for the management of pulmonary and peripheral arterial aneurysms. Retrospective case series and observational studies advise that recurrences are less common in patients who receive immunosuppressive therapy.

The proper duration of immunosuppressives after surgery is not addressed in the EULAR recommendations. Admittedly, our experience in a small series of patients with BD and aortic involvement does not allow us to conclude that long-term or even lifetime immunosuppressive therapy

can reduce or eliminate recurrent lesions; however, it is worth noting that the two patients who discontinued immunosuppressives experienced complications. Accordingly, we still advocate long-term immunotherapy as clinically feasible and the importance of close follow-up of disease activity with markers, such as ESR and CRP, and vascular imaging.

CONCLUSIONS

Our initial experience suggests that endovascular stent grafting is a reasonably safe and effective alternative to surgical repair of aortic pseudoaneurysms in patients with BD. We recommend aggressive immunosuppression therapy with an aim to normalize the ESR and CRP values preoperatively. Postoperative corticosteroid therapy and systemic immunosuppression are also critically important to prevent recurrent aneurysmal disease, including the formation of pseudoaneurysms at the site of femoral artery access and in other arteries. Unfortunately, we cannot reach any conclusion on the preferred duration of corticosteroid or immunosuppressive therapy. Further studies are necessary to clarify whether endovascular treatment combined with postoperative immunotherapy can improve the outcomes of patients with BD and aortic pseudoaneurysm.

AUTHOR CONTRIBUTIONS

Conception and design: CL

Analysis and interpretation: CL, MD

Data collection: CL, WY, BL, RZ, WW

Writing the article: CL, WY, MD

Critical revision of the article: CL, WY, BL, RZ, WW, MD

Final approval of the article: CL, WY, BL, RZ, WW, MD

Statistical analysis: Not applicable

Obtained funding: Not applicable

Overall responsibility: CL

REFERENCES

1. Kuza MA, Ozaslan C, Köksoy C, Gurler A, Tuzuner A. Vascular involvement in Behçet's disease: 8-year audit. *World J Surg* 1994;18:948-53.
2. Hamza M. Large artery involvement in Behçet's disease. *J Rheumatol* 1987;14:554-9.
3. Koç Y, Güllü I, Akpek G, Akpolat T, Kansu E, Kiraz S. Vascular involvement in Behçet's disease. *J Rheumatol* 1992;19:402.

4. Ehrlich GE. Vasculitis in Behçet's disease. *Int Rev Immunol* 1997;14:81-8.
5. Kwon TW, Part SJ, Kim HK, Yoon HK, Kim GE, Yu B. Surgical treatment result of abdominal aortic aneurysm in Behçet's disease. *Eur J Vasc Endovasc Surg* 2008;35:173-80.
6. Kalko Y, Basaran M, Aydin U, Kafa U, Basaranoglu G, Yasar T. The surgical treatment of arterial aneurysms in Behçet disease: a report of 16 patients. *J Vasc Surg* 2005;42:673-7.
7. Hosaka A, Miyata T, Shigematsu K, Okamoto H, Ishii S. Long-term outcome after surgical treatment of arterial lesions in Behçet disease. *J Vasc Surg* 2005;42:116-21.
8. Vasseur MA, Haulon S, Beregi JP, Le Tourneau T, Prat A, Warembourgh H. Endovascular treatment of abdominal aneurysmal aortitis in Behçet's disease. *J Vasc Surg* 1998;27:974-6.
9. Cekirge S, Gulsun M, Oto A, Dogan R, Balkanci F, Besim A. Endovascular treatment of an unusual arteriportal fistula caused by the rupture of a giant hepatic artery aneurysm into the superior mesenteric vein in Behçet's disease. *J Vasc Interv Radiol* 2000;11:467-564.
10. Nitecki SS, Ofer A, Karram T, Engel A, Hoffman A. Abdominal aortic aneurysm in Behçet's disease treated by endoluminal stent-graft. *Eur J Vasc Endovasc Surg* 2001;(extra)2:78-81.
11. Nitecki SS, Ofer A, Karram T, Schwartz H, Engel A, Hoffman A. Abdominal aortic aneurysm in Behçet's disease: new treatment options for an old and challenging problem. *Isr Med Assoc J* 2004;6:152-5.
12. The International Study Group for Behçet's Disease. Evaluation of diagnostic ("classification") criteria in Behçet's disease—towards internationally agreed criteria. *Br J Rheumatol* 1992;31:299-308.
13. Haskard DO. Behçet's disease. *Medicine* 2006;24:493-5.
14. Okada K, Eishi K, Takamoto S, Ando M, Kosakai Y, Nakano K, et al. Surgical management of Behçet's aortitis: a report of eight patients. *Ann Thorac Surg* 1997;64:116-9.
15. Tüzün H, Besirli K, Sayin A, Vural FS, Hamuryudan V, Hizli N, et al. Management of aneurysms in Behçet's syndrome: an analysis of 24 patients. *Surgery* 1997;121:1506.
16. Iscan ZH, Vural KM, Bayazit M. Compelling nature of arterial manifestations in Behçet disease. *J Vasc Surg* 2005;41:53-8.
17. Park JH, Chung JW, Joh JH, Song SY, Shin SJ, Chung KS, et al. Aortic and arterial aneurysms in Behçet's disease: management with stent-grafts—initial experience. *Radiology* 2001;220:745-50.
18. Koo KK, Shim WH, Yoon YS, Lee BY, Choi D, Jang Y. Endovascular therapy combined with immunosuppressive treatment for pseudoaneurysms in patients with Behçet's disease. *J Endovasc Ther* 2003;10:75-80.
19. Anderson JL, Berce M, Hartley DE. Endoluminal aortic grafting with renal and superior mesenteric artery incorporation by graft fenestration. *J Endovasc Ther* 2001;8:3-15.
20. Greenberg RK, Haulon S, Lyden SP, Srivastava SD, Turc A, Eagleton MJ, et al. Endovascular management of juxtarenal aneurysms with fenestrated endovascular grafting. *J Vasc Surg* 2004;39:279-87.
21. Greenberg RK, Haulon S, O'Neill S, Lyden S, Ouriel K. Primary endovascular repair of juxtarenal aneurysms with fenestrated endovascular grafting. *Eur J Vasc Endovasc Surg* 2004;27:484-91.
22. Hatemi G, Silman A, Bang D, Bodaghi B, Chamberlain AM, Gul A, et al. EULAR recommendation for management of Behçet's disease. *Ann Rheum Dis* 2008;67:1656-62.

Submitted Apr 10, 2009; accepted Jun 3, 2009.