



Microvasive gastric stapler: the device, technique, and preclinical results

Tom R. DeMeester, MD

*Department of Surgery, Keck School of Medicine, University of Southern California,
1510 San Pablo Street, Suite 514, Los Angeles, CA 90033-4612, USA*

Antireflux surgery is a relatively modern form of therapy for gastroesophageal reflux disease (GERD). It was initiated in the 1950s when Allison [1] recognized an association between a hiatal hernia and reflux esophagitis. He focused attention on the repair of the hernia, but the long-term benefits were minimal. Antireflux surgery assumed a more physiologic therapeutic role in the late 1970s when it was shown that a complete or partial fundoplication could correct a defective lower esophageal sphincter (LES), heal advanced mucosal injury, and control disease difficult to manage by medical therapy. During the 1980s, the outcome of antireflux procedures was improved by defining the indication for the procedure and standardizing the surgical technique. The advances in minimally invasive surgery in the 1990s allowed antireflux procedures to be performed laparoscopically. The Nissen fundoplication became the most common antireflux procedure done laparoscopically; more than 5000 patient outcomes have been reported, with a success rate of 94%, a postoperative morbidity rate of 2%, and a mortality rate of less than 0.1% [2]. The laparoscopic approach provided definitive treatment and improved patient comfort, allowed for shorter hospital stays and less convalescence, and provided a more acceptable cosmetic result. Endoscopic antireflux procedures are just beginning to be introduced. What role they have in the treatment of early or advanced GERD has yet to be determined. At present, the laparoscopic Nissen fundoplication is particularly effective in patients with early GERD and has become the gold standard to which the results of endoscopic procedures must be compared.

The principal pathophysiologic abnormality responsible for symptomatic gastroesophageal reflux is the failure of the barrier or valve between the stomach and esophagus. Repair of a failed barrier, whether through an open surgical incision, a laparoscope or, potentially, an endoscope, corrects the cause of GERD and can alter the natural history of the disease. In contrast, acid suppression therapy alters the pH of the gastric juice refluxed through the defective barrier in an effort to control the symptoms of the disease but is ineffective at correcting

the cause of the disease. If the proposed endoscopic procedures are shown to be effective, even if to a lesser degree than the laparoscopic Nissen fundoplication, they would provide the least invasive approach to correct the cause of reflux and prevent its complications. This has the possibility of shifting the focus of therapy from management to curative. Before discussing the development of an endoluminal repair, it is necessary to understand the function of a normal barrier and how it fails.

Physiology of the gastroesophageal barrier

In humans, the LES is the barrier that confines the gastric environment to the stomach. It has no anatomic landmarks, but its presence can be identified by a rise in pressure over gastric baseline pressure when a pressure transducer is pulled from the stomach into the esophagus (Fig. 1). This high-pressure zone is normally present, except in two situations: after a swallow, when it is momentarily dissipated or relaxes to allow passage of food into the stomach, and during a belch, when it allows gas to be vented from a distended fundus. The common denominator for virtually all episodes of gastroesophageal reflux is the loss of the normal high-pressure zone or barrier. When the barrier is absent, resistance to the flow of gastric juice from an environment of higher pressure—the stomach—to an environment of lower pressure—the esophagus—is lost. In early GERD, this is usually caused by a transient loss of the barrier. In advanced disease there is usually a permanent loss of the barrier [3].

There are three characteristics of this high-pressure zone, commonly referred to as the LES, that maintain its function as a barrier to intragastric and intra-abdominal pressure challenges (Fig. 1). Two of these characteristics—the overall length of the sphincter and the sphincter pressure—work together and depend on each other to provide resistance to the flow of gastric juice from the stomach into

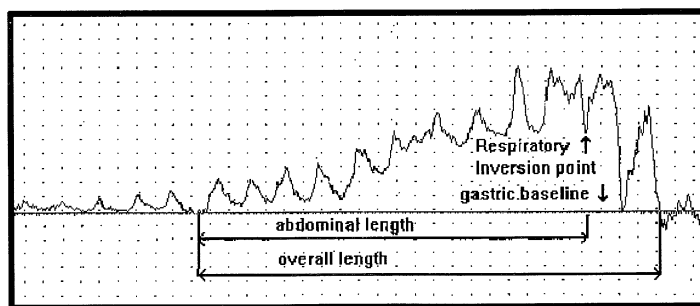


Fig. 1. A pressure profile of the lower esophageal high-pressure zone or sphincter measured in a healthy subject. Note the long intra-abdominal portion identified by the positive respiratory excursions and the short intrathoracic portion identified by the negative respiratory excursions. The point where the respiratory excursions reverse is called the respiratory inversion point. Pressure scale is 3 mm Hg between vertical dots.

the esophagus [4]. The shorter the overall length, the higher the pressure must be for the LES to maintain sufficient resistance to remain competent (Fig. 2). Consequently, the effect of a normal LES pressure can be nullified by a short overall LES length, and the effect of a normal overall LES length can be nullified by a low LES pressure. For practical purposes, the pressure of the LES is measured at a single point—the respiratory inversion point—but, in actuality, pressure is applied over the entire length of the LES. A more accurate assessment of barrier resistance is to measure the radial pressure exerted in four quadrants over the entire length of the LES. This allows the computer formation of a three-dimensional image of the LES or barrier (Fig. 3). The volume of this image reflects the LES's resistance to the flow of fluid through it. This is called the “sphincter pressure vector volume.” A calculated volume less than a one-fifth percentile of normal resting subjects indicates a permanently defective LES [5]. A fundamental principle is that the length of the barrier or sphincter is critical to its function. Shortening of LES length occurs naturally with gastric filling, as the terminal esophagus is “taken up” by the expanding fundus (Fig. 4) [6]. This is similar to the shortening of the neck of a balloon as it is inflated. With excessive gastric distention, the length of the LES shortens to a critical point at which it gives way, the pressure drops precipitously, and reflux occurs (Fig. 5) [7]. If the length of the LES is permanently short, then further shortening caused by the normal gastric distention with meals results in postprandial reflux. In this situation, competency of the barrier is an ever-constant clinical problem. The observation that gastric distention results in shortening of the LES down to a critical length so that the pressure dissipates, the lumen opens, and reflux occurs provides a mechanical explanation for transient LES relaxations (tLESRs), without invoking a neuromuscular reflex. If only the LES pressure

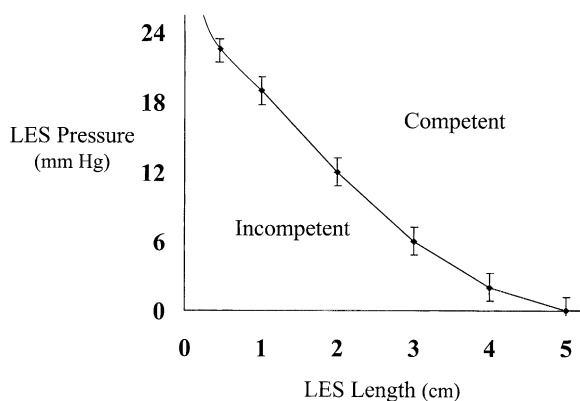


Fig. 2. The relationship of the lower esophageal sphincter (LES) pressure (measured at the respiratory inversion point) and overall LES length to the resistance to the flow of fluid through the barrier. Note that the shorter the overall length of the high-pressure zone, the higher the pressures must be to maintain sufficient resistance to remain competent. Competent, no flow; incompetent, flow of varied volumes.

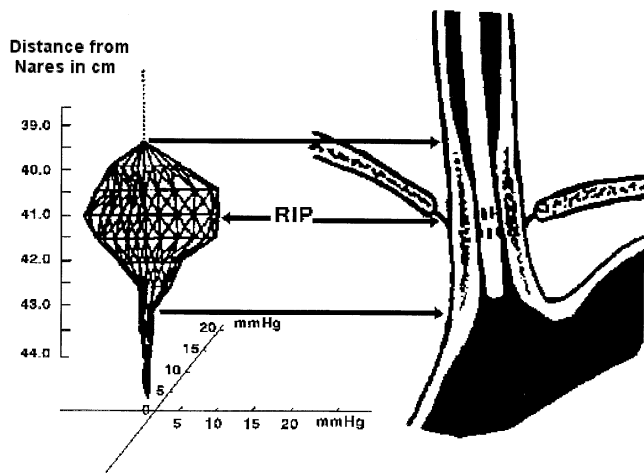


Fig. 3. A graphic illustration of how a three-dimensional computerized image of the lower esophageal sphincter (LES) can be constructed by measuring the pressure of the high-pressure zone in four quadrants at 0.5 cm intervals over the entire length of the zone. (From Stein HJ, DeMeester TR, Naspetti R, et al. Three-dimensional imaging of the lower esophageal sphincter in gastroesophageal reflux disease. *Ann Surg* 1991;214:374–84; with permission.)

and not its length is measured, as with a Dent sleeve, the event appears as a spontaneous relaxation of LES pressure [8]. In reality, it is the progressive shortening of the LES, rather than tLESRs, that results in the loss of LES pressure.

Variations in the anatomy of the cardia, from a normal acute angle of His to an abnormal dome architecture of a sliding hiatal hernia, influence the ease with

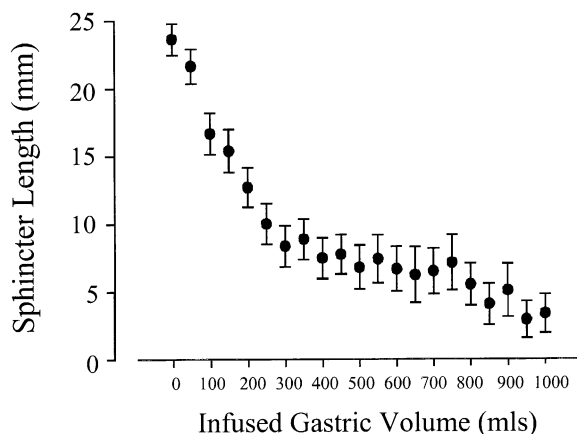


Fig. 4. The relationship between overall sphincter length to gastric distention with increasing volumes of water. (From Mason RJ, Lund RJ, DeMeester TR, et al. Nissen fundoplication prevents shortening of the sphincter during gastric distention. *Arch Surg* 1997;132:719–26.)

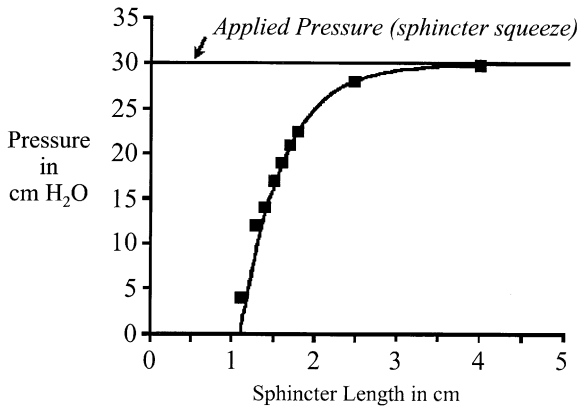


Fig. 5. The relationship between resting lower esophageal sphincter (LES) pressure measured by manometry and LES length when applied pressure or “sphincter squeeze” is kept constant. Analysis was made with a model of the LES high-pressure zone. Note that as the LES length decreases, the pressure recorded within the LES decreases only slightly, until a length of 2 cm is reached, when LES pressure drops precipitously and its competency is lost. (From Pettersson GB, Bombeck CT, Nyhus LM. The lower esophageal sphincter: mechanisms of opening and closure. *Surgery* 1980;88:307–14; with permission.)

which the sphincter is shortened by gastric distention. A hernia can result from the pulsion force of abdominal pressure on the esophageal hiatus or from the traction produced by inflammatory fibrosis of the esophageal body. The resulting alteration in the geometry of the cardia places the sphincter at a mechanical disadvantage in maintaining its length with progressive degrees of gastric distention. Greater gastric distention is necessary to open the barrier in patients with an intact angle of His than in those with a hiatal hernia [9]. This is because the dome or funnel shape of a hiatal hernia allows the wall tension forces that pull open the barrier with gastric distention to be more effectively applied to the gastroesophageal junction [10], which accounts for the common association of a hiatal hernia with GERD. Kahrilas et al [11] demonstrated this mechanical disadvantage by studying the effect of intragastric air infusion on the number of tLESRs or “shortenings” per hour. Patients with hiatal hernia had significantly more TLESRs per hour than did control subjects and those without hernias. Intragastric distention with air infusion resulted in a gradual shortening of the sphincter in all three groups. This change became significant 20 to 30 minutes after the beginning of air infusion and occurred in a distal to cephalad direction before a loss of pressure was observed.

The third characteristic of the LES high-pressure zone is its position. A portion of the overall length of the high-pressure zone is normally exposed to a positive intra-abdominal pressure environment and is commonly referred to as the abdominal length of the LES (see Fig. 1) [12]. During periods of increased intra-abdominal pressure, the resistance of the LES would easily be overcome if its position were such that abdominal pressure were unable to be applied equally to

the LES and stomach [13–15]. Think of sucking on a soft soda straw immersed in a bottle of coke; the positive hydrostatic pressure of the fluid and the negative pressure inside the straw from sucking cause the straw to collapse instead of allowing the liquid to flow up the straw in the direction of the negative pressure. If the LES is positioned so that the abdominal length is inadequate, it cannot collapse in response to applied positive intra-abdominal pressure, and the negative intra-thoracic pressure will encourage reflux to occur. Greater than 1 cm of the LES should be exposed to the abdominal pressure environment for it to respond effectively to changes in intra-abdominal pressure [16]. If the LES, in the fasting state, has an abnormally low pressure, a short overall length or minimal length exposure to the abdominal pressure environment, the result is a permanent loss of resistance with unhampered reflux of gastric contents into the esophagus. This is known as a permanently defective barrier or LES and is identified by one or more of the following characteristics: an average pressure of less than 6 mm Hg, an average overall length of >2 cm, and an average length exposed to the positive pressure environment of the abdomen of >1 cm. Compared with values for normal subjects, these values are below the 2.5 percentile for each parameter [17]. The usual cause of a permanently defective LES is inflammatory injury [18]. The most common consequence of a permanently defective LES is increased esophageal exposure to gastric juice, resulting in inflammatory injury to the mucosa and

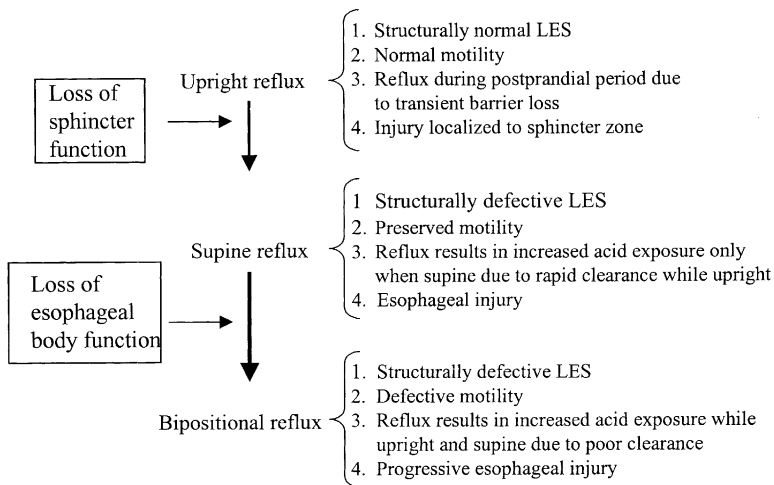


Fig. 6. Schema of the progression of gastroesophageal reflux disease (GERD). Initially, esophageal acid exposure occurs only in the upright awake position after meals from transient losses of the barrier. With inflammatory injury to the lower esophageal sphincter, the barrier becomes permanently defective and an increase in esophageal acid exposure occurs in the supine position, whereas gravity and the esophageal body effectively clears the refluxed acid during the day when upright. Inflammatory injury to the esophageal body from supine acid exposure results in the loss of esophageal body clearance function and increased esophageal acid exposure during the night and day, or bipositional reflux.

muscularis propria of the esophageal body, causing reduced contraction amplitude and abnormal waveforms. If the reflux is not brought under control, the progressive loss of effective esophageal clearance results in an ever-increasing esophageal exposure to gastric juice with further organ injury (Fig. 6) [19,20].

Causes and consequences of the failure of the gastroesophageal barrier

Early GERD is initiated by increased transient losses of the barrier secondary to gastric over distention from excessive air and food ingestion [21,22]. The tension vectors produced by gastric wall distension pull on the gastroesophageal junction resulting in the terminal esophagus being “taken up” into the stretched fundus, thereby reducing the length of the LES. With overeating, a critical length is reached, usually about 1 to 2 cm, when the sphincter gives way; its pressure drops precipitously and reflux occurs (see Fig. 4). If the swallowed air is vented gastric distension is reduced, the length of the LES is restored and competency returns until subsequent distention again shortens it and further reflux occurs. Aerophagia is common in patients with GERD because they swallow more frequently to use their saliva to neutralize the acid gastric juice refluxed into their esophagus [23]. Together, the actions of overeating and swallowing air result in the common complaint of postprandial bloating, repetitive belching, and heartburn in patients with early GERD. The high prevalence of the disease in the Western world is thought to be secondary to the eating habits of Western society [24]. Gastric distention from overeating and aerophagia along with delayed gastric emptying secondary to the increased ingestion of fatty foods lead to prolonged periods of postprandial gastric distention with shortening of the LES and repetitive transient loss of the barrier. A Nissen fundoplication prevents the shortening of the barrier with progressive degrees of gastric distention by diverting the forces produced by gastric wall tension that pull on the gastroesophageal junction [6]. The new endoscopic procedures, EndoCinch (Bard Endoscopic Technologies, Billerica, MA) and the Plicator (NDO Surgical, Mansfield, MA), attempt to do the same. Similarly, the endoscopic injection of inert materials into the area of the LES or scarring it with radiofrequency energy is an attempt to reduce the compliance of the LES, making it more resistant to the pull of gastric wall tension.

In advanced GERD, permanent loss of sphincter length occurs from inflammatory injury that extends from the mucosa into the muscular layers of the LES [3,18,26]. Fletcher et al [25] showed that, in the fasting state, there is a persistent region of high acidity in the area of the gastroesophageal junction and that this region of acidity migrates 2 cm proximally after meals. This migration occurs from distention of the stomach with eating and pulling apart of the distal high-pressure zone or LES, allowing the area of high acidity to move proximal to the squamocolumnar (SC) junction. This proximal movement exposes the distal esophageal squamous mucosa to acid, with the formation of cardiac mucosa. Cardiac mucosa is an acquired mucosa and results from inflammatory injury to the squamous mucosa in the terminal esophagus [18]. The inflammatory process

extends into the muscular layer of the LES, resulting in muscle cell injury with permanent shortening of the high-pressure zone or LES, and a concomitant reduction in the amplitude of the high-pressure zone or barrier pressure [3,18,26]. A defective barrier is recognized when the length or pressure of the LES measured during the fasting state is below the 2.5 percentile of normal [17]. For clinicians, the finding of a permanently defective LES has several implications. First, patients with a defective LES can be difficult to control symptomatically and prevent mucosal damage with medical therapy [27]. Surgery is usually required to achieve consistent long-term symptom relief, heal recalcitrant mucosal injury and interrupt the natural history of the disease. It has been shown repeatedly that a laparoscopic Nissen fundoplication can restore the length and pressure of the LES to normal [29]. Second, a permanently defective LES is commonly associated with reduced contractility and abnormal wave progression of the esophageal body [30]. This makes clearance of reflux acid difficult and leads to excessive esophageal exposure to acid. Third, a permanently defective LES and the loss of effective esophageal clearance leads to increased esophageal exposure of gastric juice with mucosal injury and the potential for Barrett metaplasia, repetitive regurgitation, aspiration, and pulmonary fibrosis [19,29,31]. At this stage of the disease, shortening of the esophageal body has usually occurred from the inflammatory injury [20,32]. A reduction of as little as 2 cm in esophageal length can place the surgical repair under too much tension and herniation of the repair into the chest or breakdown of the repair can occur. In this situation, an open antireflux procedure with complete mobilization of the thoracic esophagus and, in some situations, a gastroplasty procedure to lengthen the esophagus provide a better long-term outcome [3,32]. If the esophageal body has been severely damaged (ie, the contraction amplitude in the lower two thirds of the esophagus is globally less than 20 mm Hg), a stage of disease has been reached where a vagal sparing esophagectomy is the better option compared with an open antireflux repair.

Intraluminal transgastric valvuloplasty

With the previously described concepts in mind, an endoscopic intraluminal valvuloplasty technique was developed to provide a simple, safe, and non-invasive approach to the cardia that would prevent LES shortening during episodes of gastric distention [33]. The procedure is particularly applicable to patients with early GERD before deficiencies in the barrier and shortening of the esophageal body develop. The procedure is performed within the esophageal and gastric lumen under local anesthesia with sedation and does not require dissecting the cardia or mobilizing the short gastric vessels. Theoretically, this procedure could be performed with less morbidity than a laparoscopic antireflux procedure.

To perform an intraluminal valvuloplasty, the gastroesophageal junction is approached by way of a transgastric route using two 12-mm percutaneous, endoscopic, operating gastrostomy ports (Fig. 7) [29]. The ports are placed

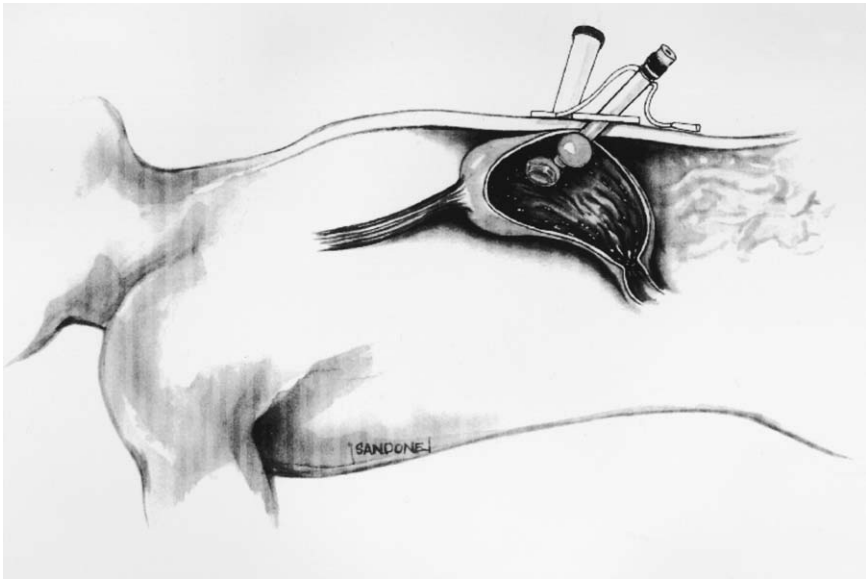


Fig. 7. Illustration of the placement of percutaneous, endoscopic, operating gastrostomy ports used to perform an intraluminal valvuloplasty of the gastroesophageal junction.

through the anterior wall of the abdomen and stomach approximately 10 cm distal to the gastroesophageal junction. The first port is inserted in the midline and orientated along the lesser curvature of the stomach. The second port is inserted 10 cm lateral to the first. A standard endoscope is passed through the esophagus into the stomach to visualize the intragastric positioning of the ports and aid in their insertion. The endoscope is removed and a specially designed 60F intraluminal invaginator is passed transorally down the esophagus while the cardia is visualized by a laparoscope placed through one of the gastrostomy ports. With inflation of the stomach through the gastrostomy ports, the squamocolumnar (SC) junction is identified. The invaginator is advanced until a marker on its surface is aligned with the SC junction. By rotating a handle on the invaginator, eight needles are advanced simultaneously at 45° angles from its surface into the esophageal mucosa. The distal esophagus is invaginated into the stomach to create a “nipple -type” valve by advancing the invaginator (Fig. 8). The intussuscepted esophagus is approximately 4 cm long and consists of full-wall thicknesses of both the distal esophagus and proximal stomach. Valve fixation is achieved with eight received staples placed in rows of two in each of the four quadrants of the intussuscepted esophagus and stomach. The first staple is placed 1.5 cm and the second 2.5 cm from the leading edge of the intussuscepted esophagus (Fig. 9). For orientation, the gastroesophageal junction is divided into quadrants. Looking cephalad, the quadrants are as follows: anterior right lateral (between lesser curve at the 9-o’clock and 12-o’clock positions anteriorly),

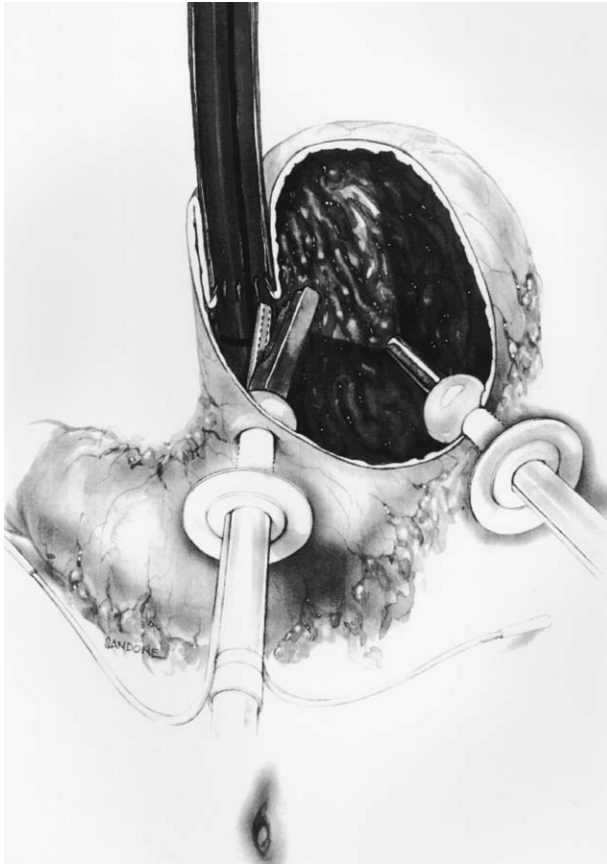


Fig. 8. Illustration of the intraluminal valvuloplasty procedure. The invaginator advances the distal esophagus into the stomach to form a nipple-type valve which is fixed by stapling the intussuscepted esophageal and gastric wall with a stapling instrument inserted through the gastrostomy port.

anterior left lateral (between the 12-o'clock position anteriorly and the greater curvature at the 3-o'clock position), posterior left lateral (between the greater curvature at the 3-o'clock and 6-o'clock positions posteriorly), posterior right lateral (between the 6-o'clock position posteriorly and the lesser curve at the 9-o'clock position). The staples are placed as close to the lesser curve as possible in the anterior right lateral and posterior right lateral quadrant. The staples have a 3×6 -mm flat surface on each side to buttress their purchase on the tissue. Two legs that extend from the esophageal face plate penetrate the invaginated esophageal and gastric walls and lock securely within the intragastric face plate.

The procedure was technically feasible in 13 baboons. There were no intra-operative complications and all animals survived with no 30-day mortality. All animals were able to swallow satisfactorily 12 hours after the procedure. Fruits and vegetables were slowly reintroduced into the daily diet and all baboons were

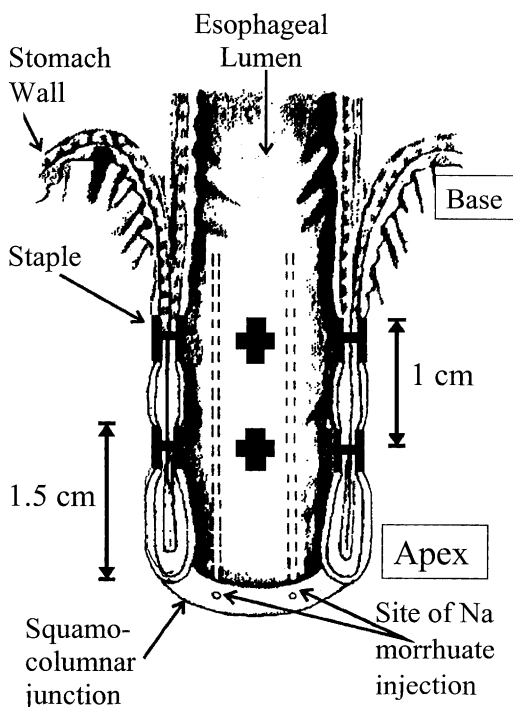


Fig. 9. A cross-sectional diagrammatic view of the intussuscepted gastroesophageal junction showing the completed valvuloplasty, depicting the thickness of the invaginated wall of the esophagus and stomach, the physical dimensions of the valve, and the site of staples. (From Mason RJ, Filipi CJ, DeMeester TR, et al. A new intraluminal antigastroesophageal reflux procedure in baboons. *Gastrointest Endosc* 1997;45:283–90; with permission.)

on a normal diet 2 weeks after surgery. Over the 6-month follow-up period there was no evidence of feeding difficulty, vomiting, or weight loss.

Endoscopic examination of the esophagus in 12 baboons 6 months after the procedure showed no macroscopic evidence of esophagitis or stricture formation. Small shallow indentations or diverticula of the esophageal mucosa at the suspected staple sites were noted in 10 baboons. Retroflexed examination of the gastric surface of the valve showed mild inflammatory polyps and reactive mucosal hyperplasia around the staple sites in 10 of 12 baboons. Staples were visible on the gastric side in only 2 baboons. Most staples were imbedded in the tissue and covered with mucosa. A nipple-type valve was visible in all baboons (Fig. 10). The integrity of the valve was noted to be completely intact circumferentially in 6 baboons. Partial deterioration occurred in the remaining 6 animals, giving an overall valve circumference integrity of 86%. A resistance to distraction and opening of the LES with air insufflation of the stomach was noted in all baboons. The valvuloplasty seemed to interrupt the mechanical forces that pull open and “unfold” the sphincter during gastric distention. The striking

Endoscopic Nissen

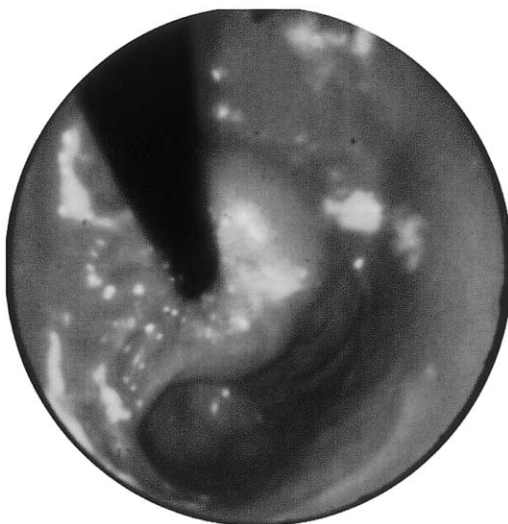

Fig. 10. A retroflexed endoscopic view of an endoscopic intraluminal valvuloplasty in a baboon at 6 months postprocedure. (See also Color Plate 2.)

improvement in the retroflexed view of the cardia on gastric insufflation was similar to what Ismail et al [9] has described in humans. The authors showed that a higher pressure was needed to open the LES in patients with an acute angle of His and a seminipple valvular geometry compared with those with a wide angle of His and no valvular geometry.

Manometry and pressure-volume testing confirmed that the valvuloplasty procedure significantly improves and augments the mechanical characteristics of the LES. After the valvuloplasty procedure, the overall and abdominal length of the LES increased, whereas the pressure remained unchanged (Table 1). Distention of the stomach with water caused a smaller reduction in LESr length

Table 1

LES characteristics before and after the operation for the valvuloplasty group^a

Characteristic	Preoperative	Postoperative	P value
Total LES length, mm	22 (2.5)	30 (7.9)	0.003
Intra-abdominal length, mm	14 (4.5)	22 (1.3)	0.045
LES pressure, mm Hg	6.5 (2.7)	6.8 (9.5)	0.326
Sphincter vector volume, mL	2175 (1350)	2484 (8433)	0.054

Abbreviation: LES, lower esophageal sphincter.

^a Values are medians and interquartile range.

Data from Mason RJ, Filipi CJ, DeMeester TJ, et al. A new intraluminal antigastroesophageal reflux procedure in baboons. *Gastrointest Endosc* 1997;45:283–90.

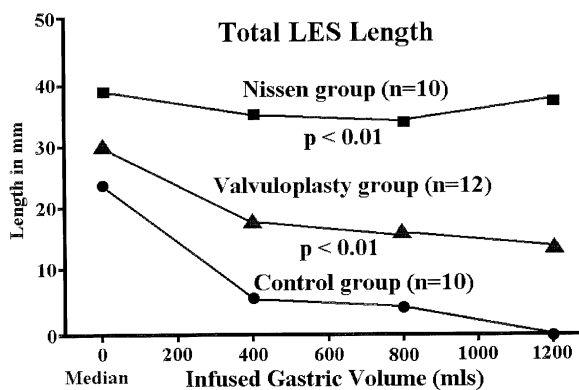


Fig. 11. Change in length of the lower esophageal sphincter (LES) following gastric distention with increasing volumes of water in control baboons, after an endoscopic intraluminal valvuloplasty, and after a Nissen fundoplication.

compared with control baboons but did not provide as much protection as a Nissen fundoplication (Fig. 11). This in turn resulted in greater competency of the LES as shown by an increase in the median yield pressure from 12.75 mm Hg in the control group to 22.87 mm Hg in the valvuloplasty group and an increase in the median yield volume from 825 to 1525 mL, respectively. Both measurements were significant at the $P < 0.01$ level. The increase in fundic pressure to infused intragastric volume was similar in the control and valvuloplasty animals (Fig. 12). Despite this finding, the number of competent valves in the control baboons progressively decreased with increasing volume or pressure when compared

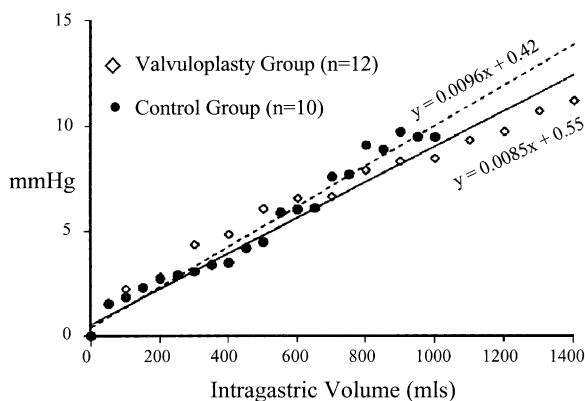


Fig. 12. Changes in fundic pressure (mm Hg) in response to infused intragastric volume (mL) in control baboons and after an endoscopic intraluminal valvuloplasty. A significant linear correlation was noted for each group. The response in both groups was similar. (From Mason RJ, Filipi CJ, DeMeester TR, et al. A new intraluminal antigastroesophageal reflux procedure in baboons. *Gastrointest Endosc* 1997;45:283–90; with permission.)

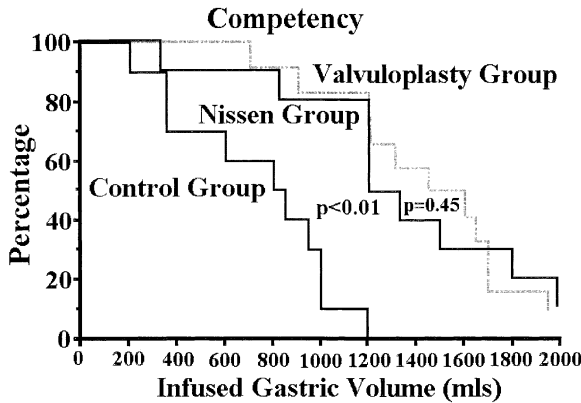


Fig. 13. Percentage of competency at various degrees of gastric distention with water (mL) for control baboons, those with an endoscopic intraluminal valvuloplasty, and those with a Nissen fundoplication. There was a significant difference between the control and valvuloplasty baboons. (From Mason RJ, Filipi CJ, DeMeester TR, et al. A new intraluminal antigastroesophageal reflux procedure in baboons. *Gastrointest Endosc* 1997;45:283–90; with permission.)

with the valvuloplasty group (Figs. 13,14). This difference was significant at the $P < 0.01$ level. The baboons with a valvuloplasty compared well with those with a Nissen fundoplication when water was used rather than air for gastric distention. These findings indicate that the improved competency of the valvuloplasty group occurred because of the protection the valvuloplasty provided against a reduction in LES length with increased gastric distention.

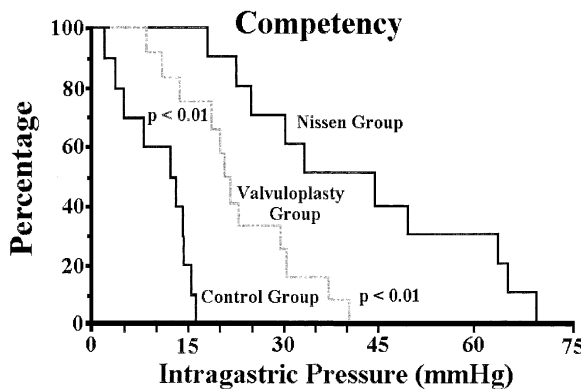


Fig. 14. Percentage of competency at various degrees of gastric distention with air for control baboons, those with an endoscopic intraluminal valvuloplasty, and those with a Nissen fundoplication. There was a significant difference between all groups. (From Mason RJ, Filipi CJ, DeMeester TR, et al. A new intraluminal antigastroesophageal reflux procedure in baboons. *Gastrointest Endosc* 1997;45:283–90; with permission.)

These experiments showed that an intraluminal valvuloplasty of the gastro-esophageal junction is technically feasible and that intra-abdominal surgical dissection or mobilization of the stomach or cardia is not necessary. The results further suggest a low morbidity of the intraluminal approach when applied to humans. Other approaches attempt to bolster the gastroesophageal junction and prevent shortening of the LES with gastric distention by the submucosal injection of collagen [34] or a foreign material [35], or induce fibrosis of the junction with chemical [36], laser, or radiofrequency injury. The short-term results of the alternative procedures appear favorable; however, none of the techniques has been shown to increase the LES length, improve competency with gastric distention, or retain durability with time [37]. In contrast, the valvuloplasty described used nonabsorbable staples that resulted in an inflammatory reaction and a fibrotic doughnut, which the authors believe is responsible for the stability of the valve in more than 70% of the animals after 6 months. The trade-off for this durability is the staple-associated pathology of hyperplastic mucosa, diverticula, and inflammatory polyps. The reconfiguration of the geometry of the cardia into a nipple valve increases the overall length of the LES and augments the competency of the cardia by resisting the mechanical forces that pull open and shorten the LES during gastric distention.

In conclusion, overeating and a high-fat diet most likely result in delayed gastric emptying, prolonged gastric distention, shortening of the LES and increases exposure of the squamous mucosa of the lower esophagus and sphincter area to gastric juice. This repetitive exposure causes an injurious inflammatory response with transmural injury in LES, which results in gradual deterioration of the LES function to where it becomes permanently defective with extension of the disease into the esophageal body. Prevention of unfolding and shortening of the LES during periods of gastric distention is required to interrupt the progression at an early stage. The development of the intraluminal valvuloplasty shows that by a simple mechanical means, the LES length can be increased and its shortening prevented, resulting in improved competency. The procedure was specifically developed to interrupt the progression of GERD at an early stage before LES deterioration has occurred. The technique, when fully developed, potentially will allow for a totally endoscopic procedure performed in an outpatient endoscopy suite and change the focus of therapy of GERD from management to curative.

References

- [1] Allison PR. Reflux esophagitis, sliding hiatal hernia and the anatomy of repair. *Surg Gynecol Obstet* 1951;92:419–31.
- [2] Carlson MA, Frantzidez CT. Complications and results of primary minimally invasive antireflux procedure. A review of 10,735 reported cases. *J Am Coll Surg* 2001;193:429–39.
- [3] DeMeester TR, Peters JH, Bremner CG, Chandrasoma P. Biology of gastroesophageal reflux disease: pathophysiology relating to medical and surgical treatment. *Annu Rev Med* 1999;50:469–506.

- [4] Bonavina L, Evander A, DeMeester TR, et al. Length of the distal esophageal sphincter and competency of the cardia. *Am J Surg* 1986;151:25–34.
- [5] Stein HJ, DeMeester TR, Nassetti R, et al. Three-dimensional imaging of the lower esophageal sphincter in gastroesophageal reflux disease. *Ann Surg* 1991;214:374–84.
- [6] Mason RJ, Lund RJ, DeMeester TR, et al. Nissen fundoplication prevents shortening of the sphincter during gastric distention. *Arch Surg* 1997;132:719–26.
- [7] Petterson GB, Bombeck CT, Nyhus LM. The lower esophageal sphincter: mechanisms of opening and closure. *Surgery* 1980;88:307–14.
- [8] Dent J. A new technique for continuous sphincter pressure measurement. *Gastroenterology* 1976;71:263–7.
- [9] Ismail T, Bancewicz J, Barlow J. Yield pressure, anatomy of the cardia and gastroesophageal reflux. *Br J Surg* 1995;82:943–7.
- [10] Marchand P. The gastro-oesophageal “sphincter” and the mechanism of regurgitation. *Br J Surg* 1955;42:504–13.
- [11] Kahrilas PJ, Shi G, Manka M, Joehl RJ. Increased frequency of transient lower esophageal sphincter relaxation induced by gastric distention in reflux patients with hiatal hernia. *Gastroenterology* 2000;118:688–95.
- [12] DeMeester TR, Wernly JA, Bryant GH, et al. Clinical and in vitro analysis of gastroesophageal competence: a study of the principles of antireflux surgery. *Am J Surg* 1979;137:39–46.
- [13] Pellegrini CA, DeMeester TR, Skinner DB. Response of the distal esophageal sphincter to respiratory and positional maneuvers in humans. *Surg Forum* 1976;27:380–2.
- [14] O’Sullivan GC, DeMeester TR, Joelsson BE, et al. The interaction of the lower esophageal sphincter pressure and length of sphincter in the abdomen as determinants of gastroesophageal competence. *Am J Surg* 1982;143:40–7.
- [15] Johnson LF, Lin YC, Hong SK. Gastroesophageal dynamics during immersion in water to the neck. *J Appl Physiol* 1975;38:449–54.
- [16] DeMeester TR, Wernly JA, Bryant GH, et al. Clinical and in vitro analysis of gastroesophageal competence: a study of the principles of antireflux surgery. *Am J Surg* 1979;137:39–46.
- [17] Zaninotto G, DeMeester TR, Schwizer W, et al. The lower esophageal sphincter in health and disease. *Am J Surg* 1988;155:104–11.
- [18] Öberg S, Peters JH, DeMeester TR, et al. Inflammation and specialized intestinal metaplasia of cardiac mucosa is a manifestation of early gastroesophageal reflux disease. *Ann Surg* 1997;226:522–32.
- [19] Stein HJ, Barlow AP, DeMeester TR, Hinder RA. Complications of gastroesophageal reflux disease: role of the lower esophageal sphincter, esophageal acid and acid/alkaline exposure, and duodenogastric reflux. *Ann Surg* 1992;216:35–43.
- [20] Zaninotto G, DeMeester TR, Bremner CG, et al. Esophageal function in patients with reflux-induced strictures and its relevance to surgical treatment. *Ann Thorac Surg* 1995;47:362–70.
- [21] DeMeester TR, Ireland AP. Gastric pathology as an initiator and potentiator of gastroesophageal reflux disease. *Dis Esophagus* 1997;10:1–8.
- [22] Barham CP, Gotley DC, Mills A, Alderson D. Precipitating causes of acid reflux episodes in ambulant patients with gastro-oesophageal reflux disease. *Gut* 1995;36:505–10.
- [23] Bremner RM, Hoelt SF, Costantini M, et al. Pharyngeal swallowing: the major factor in clearance of esophageal reflux episodes. *Ann Surg* 1993;218:364–70.
- [24] Iwakiri K, Kobayashi M, Kotoyari M, et al. Relationship between postprandial esophageal acid exposure and meal volume and fat content. *Dig Dis Sci* 1996;41:926–30.
- [25] Fletcher J, Wirz A, Young J, et al. Unbuffered highly acidic gastric juice exists at the gastroesophageal junction after a meal. *Gastroenterology* 2001;121:775–83.
- [26] Theisen J, Öberg S, Peters JH, et al. Gastro-oesophageal reflux disease confined to the sphincter. *Dis Esophagus* 2001;14:235–8.
- [27] Kuster E, Ros E, Toledo-Pimentel V, et al. Predictive factors of the long term outcome in gastro-oesophageal reflux disease: six year follow up of 107 patients. *Gut* 1994;35:8–14.

- [28] Peters JH, DeMeester TR, Crookes P, et al. The treatment of gastroesophageal reflux disease with laparoscopic Nissen fundoplication. *Ann Surg* 1998;228:40–50.
- [29] Tsai P, Peters J, Johnson W, et al. Laparoscopic fundoplication 1 month prior to lung transplantation. *Surg Endosc* 1996;10:668–70.
- [30] Singh P, Adamopoulos A, Taylor RH, Colin-Jones DG. Oesophageal motor function before and after healing of oesophagitis. *Gut* 1992;33:1590–6.
- [31] Stein JH, Eypasch EP, DeMeester TR, Smyrk TC. Circadian esophageal motor function in patients with gastroesophageal reflux disease. *Surgery* 1990;108:769–78.
- [32] Gastal O, Hagen JA, Peters JH, et al. Short esophagus: analysis of predictors and clinical implications. *Arch Surg* 1999;134:633–8.
- [33] Mason RJ, Filipi CJ, DeMeester TR, et al. A new intraluminal antigastroesophageal reflux procedure in baboons. *Gastrointest Endosc* 1997;45:283–90.
- [34] O'Connor K, Lehman G. Endoscopic placement of collagen at the lower esophageal sphincter to inhibit gastroesophageal reflux: a pilot study of 10 medically intractable patients. *Gastrointest Endosc* 1988;34:106–12.
- [35] Shafik A. Intraesophageal Polytef injection for the treatment of reflux esophagitis. *Surg Endosc* 1996;10:329–31.
- [36] Donahue PE, Carvalho P, Yoshida J, et al. Endoscopic sclerosis of the cardia affects gastroesophageal reflux. *Surg Endosc* 1989;3:11–2.
- [37] Donahue PE, Sugitani A, Carvalho P. Endoscopic control of gastro-esophageal reflux: status report. *World J Surg* 1992;16:343–6.