

## EDUCATIONAL ARTICLE

# Autogenous Options in Secondary and Tertiary Access for Haemodialysis

J.H.M. Tordoir,<sup>1\*</sup> X. Keuter,<sup>1</sup> N. Planken,<sup>1</sup> M.W. de Haan<sup>2</sup> and F.M. van der Sande<sup>3</sup>

Departments of <sup>1</sup>Surgery, <sup>2</sup>Radiology, and <sup>3</sup>Nephrology, University Hospital Maastricht, Maastricht, The Netherlands

*Objectives:* The world's haemodialysis population is growing rapidly so that in 2006, some 1.5 million interventions will be needed for access placement, revision and maintainance. Secondary and tertiary arteriovenous fistulas are becoming an integral part of vascular access especially in the elderly, comorbid population.

*Methods:* Venous conduits may have a more favourable outcome with fewer complications and revisions in comparison with accesses using prosthetic implants. Innovative surgical techniques, including vein transposition, translocation and elevation may add to this philosophy of creating exclusively autogenous vascular access.

*Keywords:* Autogenous fistula; Secondary access; Tertiary access; Haemodialysis

### Introduction

For decades the strategies for access creation have been different in Europe and the USA with the majority of new and incident patients receiving autogenous arteriovenous fistulas (AVF) in Europe, whereas in the USA most have received prosthetic grafts. Although there is still a clear preference for primary autogenous radial-cephalic arteriovenous fistulas (RCAVF) in European countries, the need for secondary and tertiary procedures in Europe is increasing due the increasing age of dialysis patients and associated comorbidities such as diabetes mellitus, coronary artery disease and peripheral arterial disease, which may hamper the creation of autogenous vascular access conduits. Recently published data still show a high prevalence of autogenous AVFs among European patients, but there seems to be a major shift in secondary and tertiary procedures from forearm fistulas to elbow and upper arm fistulas.<sup>1</sup> In addition, the difficulties encountered

by many physicians in creating a functioning vascular access has led to a renewed interest in the exclusive use of the patient's own veins for fistula creation.

In this review the strategies, surgical techniques and outcomes of the creation of secondary and tertiary accesses with the use of upper and lower extremity venous conduits are described.

### Secondary/Tertiary Autogenous Fistulas in the Upper Extremity

The upper limb is preferred over the lower extremity for vascular access because of the ease of cannulation, comfort for the patient and the considerably lower incidence of complications. Similarly, autogenous conduits are also preferable to the use of prosthetic grafts because of improved patency and lower risk of infection.

#### *Forearm venous transposition and elevation*

Superficial vein transposition increases the possibilities for forearm fistulas. When the cephalic vein is unsuitable the basilic vein can be transposed from the

Update on Renal Access and Transplantation—one of a series of educational articles edited by Mr Christopher Gibbons, Swansea, UK.

\*Corresponding author. Dr Jan HM Tordoir, Department of Surgery, University Hospital Maastricht, P Debijelaan 25, 6202 AZ, Maastricht, The Netherlands.

E-mail address: [j.tordoir@surgery.azm.nl](mailto:j.tordoir@surgery.azm.nl)

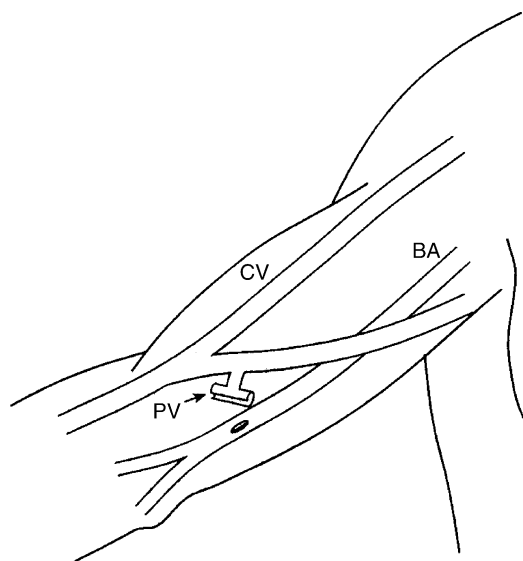
ulnar to the radial side along a straight subcutaneous course from the elbow to the radial artery. Silva *et al.*<sup>2</sup> advocated different surgical techniques, according to the forearm artery and vein location. Of the 89 veins that were of acceptable size and patency, 13 (15%) were in immediate proximity to the radial artery such that an AVF could be formed through a single incision. Thirty of 89 (33%) of the veins were located on the dorsal aspect of the forearm and were transposed to the volar aspect for anastomosis to the appropriate artery (radial in 26, ulnar in two, and brachial in two). The remaining 46 of 89 veins (52%) were located on the volar aspect of the forearm but were dissected through separate incisions, transposed superficially, and sutured to the appropriate artery (radial in 42, ulnar in two, and brachial in two). Successful cannulation and hemodialysis was accomplished in 81 of the 89 AVFs, giving a maturation rate of 91%. Primary patency rates were 84% at 1 year and 69% at 2 years for all AVFs.

When the arterial inflow into a radial fistula is impeded by a distal stenosis in the forearm, it may be enhanced by transposition of the forearm cephalic or basilic vein more proximally to the radial artery or brachial artery at the elbow in a subcutaneous loop.<sup>3</sup>

A cephalic vein that is located too deeply may be made accessible for cannulation by elevation. Four to 9 weeks after the initial operation, the cephalic vein has usually matured sufficiently to allow easy surgical dissection. The subcutaneous fat is approximated beneath the fistula vein, thereby elevating the fistula to a superficial position. An alternative surgical option is cephalic vein dissection and transection 2 cm proximal to the AV anastomosis with subcutaneous rerouting along a straight course with reanastomosis to the radial artery. The elevation technique has been described by Cull *et al.* in seven patients with RCAVFs and cannulation difficulties. The failure rate was rather high with five out of seven elevated fistulas non-functional for dialysis treatment.<sup>4</sup>

#### *Mid-forearm and elbow AVF*

When the arteries and/or veins are too small or diseased for the creation of a wrist RCAVF, more proximally located fistulas are indicated with an anastomosis at the mid-forearm or elbow region. Konner *et al.* have shown that in a high percentage of patients with failed RCAVFs still a suitable vein can be found proximal in the forearm, which can be anastomosed to the radial artery.<sup>5</sup> Bonforte *et al.* have described the surgical technique of mid-forearm fistula. A total of 112 surgical procedures were



**Fig. 1.** Brachial-cubital AVF (Gracz). BA, brachial artery; PV, perforating vein; CV, cephalic vein.

performed on 106 patients with primary 24- and 48-month patency rates of 93 and 83%, respectively, and a low incidence of complications.<sup>6</sup>

In brachial-cubital AVFs (Gracz fistula), the deep perforating branch of the medial cubital vein is dissected, transected and anastomosed to the brachial or proximal radial artery (Fig. 1). The flow through the AVF will be directed either to the upper arm basilic and/or cephalic vein, which becomes available for cannulation. Brachial-cubital AVFs generate a high blood flow for dialysis. The incidences of non-maturation, thrombosis and infection are low with good long-term patency. In 50 patients with brachio-cubital AVFs, the 1- and 3-year patencies were 84 and 78%, respectively. Major complications were distal hypoperfusion, which may lead to symptomatic hand ischaemia, and high-output cardiac failure, especially in patients with heart disease and coronary artery sclerosis.<sup>7</sup>

#### *Upper arm brachial-cephalic AVF*

The brachial-cephalic AV fistula is only one of a variety of possible AV anastomoses in the elbow region. Depending on the individual situation, the proximal radial artery, brachial artery or proximal ulnar artery can be used for the AV anastomosis (Fig. 2). As for forearm fistulas, the vascular access should provide an optimal situation for cannulation along the cephalic vein.

Recently, the results of 100 brachial-cephalic fistulas in 96 patients were reported, with the majority of patients receiving a brachial artery to cubital vein

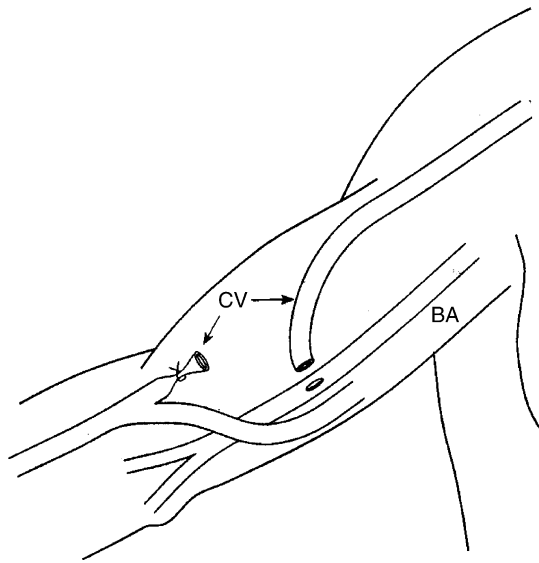


Fig. 2. Brachial-cephalic AVF. BA, brachial artery; CV, cephalic vein.

anastomosis. The primary, primary assisted, and secondary patency rates after 1 year were 54.7, 72.3 and 79.2%, and after 2 years 40.4, 59.2 and 67.5%, respectively. Predictors of failure, using Cox regression multivariate analysis, included diabetes mellitus (HR 2.81,  $p < 0.001$ ) and a history of contralateral PTFE loop graft (HR 7.79,  $p = 0.007$ ). The authors concluded that the primary patency of brachial-cephalic fistulas was comparable to that of radial-cephalic fistulas.<sup>8</sup> Reported early failure and 1-year patency rates of brachial-cephalic AVFs are outlined in Table 1.<sup>8-13</sup>

*Upper arm brachial-basilic AVF*

Usually the upper arm basilic vein is inaccessible for dialysis cannulation, because of its medial and deep native position. In 1976, Dagher *et al.*<sup>14</sup> described the original technique of brachial-basilic anastomosis with a second operation to mobilise the arterIALIZED vein into a subcutaneous position. There are several surgical options for brachial-basilic AVFs (BBAVF):

Table 1. Early failure and 1-year patency of brachial-cephalic AVFs

Author	No AVFs	Early failure (%)	Patency (%)
Dunlop <i>et al.</i> <sup>9</sup>	81	–	70
Zibari <i>et al.</i> <sup>10</sup>	48	–	90
Nazzal <i>et al.</i> <sup>11</sup>	42	–	91
Murphy <i>et al.</i> <sup>12</sup>	208	16	75
Zeebregts <i>et al.</i> <sup>8</sup>	100	11	79
Lok <i>et al.</i> <sup>13</sup>	186	9	78

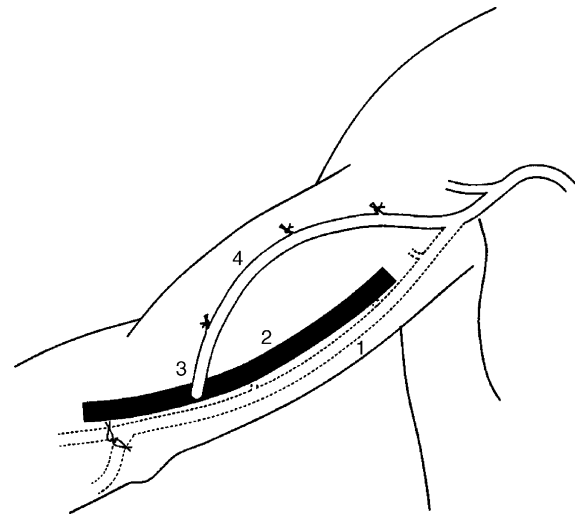


Fig. 3. Brachial-basilic AVF. 1, basilic vein in its normal position; 2, brachial artery; 3, transposed basilic vein.

- *One-stage procedure:* The basilic vein is dissected and side branches ligated from the elbow to the axilla. After transection at the elbow it is transposed through a lateral subcutaneous tunnel and reanastomosed end-to-side to the brachial artery (Fig. 3).
- *Two-stage procedure:* At the first operation a brachial artery to basilic vein anastomosis is performed. Six weeks later a second procedure is performed using one of two alternative techniques for superficialisation of the vein:
  - (a) *Elevation:* The basilic vein is dissected and the side branches ligated. The fat is sutured beneath the vein, elevating it to a subcutaneous position.
  - (b) *Transposition:* The basilic vein is dissected out, the sidebranches ligated and transected 2 cm proximal to the AV anastomosis. It is then passed laterally through a subcutaneous tunnel and reanastomosed to the brachial artery.

No significant differences in non-maturation and patency rates have been reported between one and two-stage procedures. The elevation and transposition techniques also have similar outcomes. Rivers *et al.*<sup>15</sup> found that 49% of one stage BBAVFs were patent at 30 months. Hossny<sup>16</sup> employed the different techniques of BBAVF creation in a non-randomised study of 70 patients. High one-year patencies from 86 to 90% in all groups were reported with only 5–7% of AVF showing non-maturation. Recent publications report a primary failure rate of 5–40% with 1-year patencies varying from 47 to 90% (Table 2).<sup>15-23</sup> The technique of

**Table 2. Early failure and 1-year patency of brachial-basilic AVFs**

Author	Type AVF	No. AVFs	Early failure (%)	Patency (%)
Rivers <i>et al.</i> <sup>15</sup>	os/tr	65	2	58
Coburn <i>et al.</i> <sup>17</sup>	os/tr	59	–	93
El Mallah <i>et al.</i> <sup>18</sup>	os/tr	20	40	50
	ts/el	20	10	80
Humphries <i>et al.</i> <sup>19</sup>	ts/el	67	–	84
Murphy <i>et al.</i> <sup>20</sup>	os/tr	74	32	73
Segal <i>et al.</i> <sup>21</sup>	os/tr	99	23	64
Taghizadeh <i>et al.</i> <sup>22</sup>	os/tr	75	8	66
	os/el	20	5	90
Hossny <sup>16</sup>	os/tr	20	7	86
	ts/el	30	5	87
Rao <i>et al.</i> <sup>23</sup>	os/tr	56	38	47

Os, one stage; Ts, two stage; Tr, transposition; El, elevation.

subcutaneous placement of the basilic vein seems to have several advantages over forearm or upper arm graft implantation, with less infection and thrombosis. In comparison with brachial-cephalic fistulas, BBAVFs are more likely to mature, although they are more susceptible to late thrombosis.

#### *Upper arm brachial-brachial vein AVF*

Recently a transposition fistula using the brachial vein in the upper arm has been described for vascular access in two patients.<sup>24</sup> As in basilic vein transposition, the brachial vein is harvested distally about 3 cm into the forearm beyond the antecubital fossa, in order to gain sufficient length for lateral tunnelling. The vein is ligated at this level, transected and transposed through a subcutaneous tunnel lateral to the incision. The non-distended brachial vein is about 4–5 mm in diameter and may increase to 6–8 mm under pressure. A period of 8 weeks is allowed for the fistula to mature prior to its use for haemodialysis.

#### *Upper arm brachial-axillary translocated superficial femoral vein*

The superficial femoral vein is a large autogenous vein that can be translocated to the upper extremity. It is exposed through an incision that extends from the inferior aspect of the femoral triangle over the common femoral vein to the above-knee popliteal fossa on the lateral aspect of the sartorius muscle. The superficial femoro-popliteal vein is then dissected free caudally from its confluence with the profunda femoral vein to the midpopliteal fossa. After removal, the reversed vein is interposed through a subcutaneous tunnel between the brachial artery and axillary vein. Huber *et al.*<sup>25</sup> reported on the outcome of 30 superficial femoral vein (SFV) translocations.

The primary, primary assisted, and secondary patency rates for the SFV were 79, 91, and 100%, respectively, at 12 months; and 67, 86, and 100%, respectively, at 18 months. Significant hand ischaemia developed in 43% of the patients and required a DRIL procedure in 27%. Thigh wound complications developed in 23% of the patients, and arm wound complications developed in 17%. There was a significant difference in the incidence of thigh complications between obese and non-obese patients (57 *vs.* 13%). One patient with PAOD required an above-knee amputation ipsilateral to the deep vein harvest, and a second patient with a failing DRIL procedure required a finger amputation.

### **Secondary/Tertiary Autogenous Fistulas in the Lower Extremity**

The lack of potential upper extremity or chest wall AVF sites, due to exhaustion of all upper extremity outflow veins by catheter-induced central venous obstruction, makes vascular access at the femoral region inevitable for a growing number of patients. Saphenous and superficial femoral vein transposition are options for thigh AVFs.

#### *Lower extremity femoral-greater saphenous vein access*

The greater saphenous vein can be used for vascular access in either of two ways:

- It may be transposed in a straight subcutaneous tunnel with anastomosis to the superficial femoral artery above the knee. The main advantage of this technique is its long subcutaneous course available for cannulation.<sup>26</sup>
- The second surgical option is transposition in a looped fashion with the AV anastomosis to the groin femoral artery.

#### *Lower extremity femoral-superficial femoral vein access*

Gradman *et al.*<sup>27</sup> have described the technique of superficial femoral vein (SFV) transposition. The superficial femoral vein, in continuity with a variable length of supragenicular popliteal vein, is mobilized from the popliteal fossa to the junction of the femoral vein with the profunda femoris vein. The vein is transposed superficially and anastomosed to the distal femoral artery (Fig. 4). The vein is usually suture banded primarily to avoid distal ischaemia due to steal from the high fistula flow.

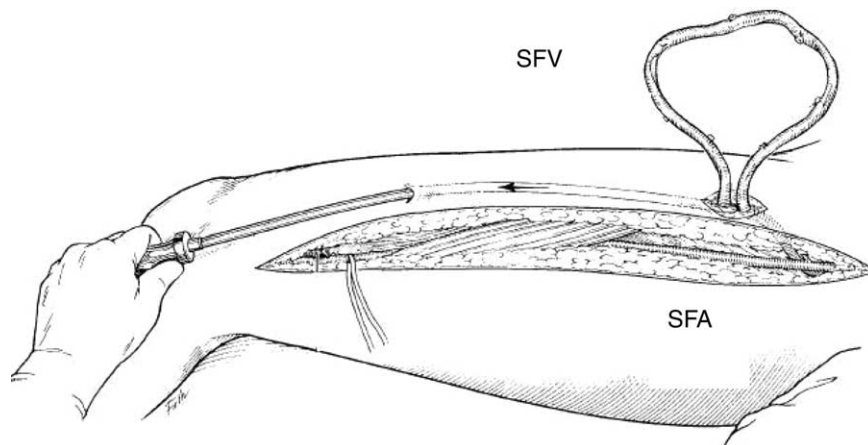


Fig. 4. Superficial femoral vein transposition. SFA, superficial femoral artery; SFV, superficial femoral vein.

The results of elective construction of a SFV fistula were reported in 54 patients.<sup>27</sup> The first patients underwent intraoperative access banding and when indicated a femoropopliteal bypass graft or a composite prosthetic-femoral vein to groin femoral artery looped access was performed in patients with peripheral arterial obstructive disease (PAOD). More recently, patients with known PAOD were excluded. Patients without PAOD that were included underwent a variety of measures to avoid ischaemia, including tapering of the femoral vein at the takeoff from the distal femoral artery and compartment fasciotomies when pulses were very weak or absent immediately after access construction. In the total patient group, 10 accesses were banded either intraoperatively (6) or in the immediate postoperative period (4) to avoid or treat ischaemia. Nine patients (16%) showed evidence of ischaemia in the postoperative period. Procedures to alleviate ischaemia included various combinations of distal bypass without interval ligation, conversion to a looped access, iliac artery angioplasty, fasciotomy, access banding, and access ligation. One patient eventually had an above-knee amputation. In this study no major wound complications or graft infections were reported. However, in another study there was a rather high incidence of ischaemia and infection (30 and 27%, respectively).<sup>28</sup>

### Summary

- The percentage of autogenous vascular access in elderly, comorbid and obese patients can be increased considerably by innovative surgical procedures, including elevation and/or transposition of deeply or dorsally positioned veins.
- Upper extremity secondary/tertiary autogenous access conduits with transposed veins have

patency rates comparable to primary radial-cephalic AVFs.

- The surgical technique of brachial-basilic AVF (one vs. two-stage procedure; vein transposition vs. elevation) results in similar non-maturation and 1-year patency rates.
- Lower extremity access by femoral vein transposition is an acceptable alternative in case of upper extremity outflow obstruction, but exhibits a high incidence of ischaemia and infection.

### References

- 1 PISONI RL, YOUNG EW, DYKSTRA DM, GREENWOOD RN, HECKING E, GILLESPIE B *et al.* Vascular access use in Europe and the United States: results from the DOPPS. *Kidney Int* 2002; **61**(1):305–316.
- 2 SILVA MB, HOBSON RW, PAPPAS PJ, HASER PB, ARAKI CT, GOLDBERG MC *et al.* Vein transposition in the forearm for autogenous hemodialysis access. *J Vasc Surg* 1997; **26**:981–986.
- 3 GEFEN JY, FOX D, GIANGOLA G, EWING DR, MEISELS IS. The transposed forearm loop arteriovenous fistula: a valuable option for primary hemodialysis access in diabetic patients. *Ann Vasc Surg* 2002; **16**:89–94.
- 4 CULL DL, TAYLOR SM, CARSTEN CG, YOUKEY JR, SNYDER BA, SULLIVAN TM *et al.* The fistula elevation procedure: a valuable technique for maximizing arteriovenous fistula utilization. *Ann Vasc Surg* 2002; **16**:84–88.
- 5 KONNER K. Primary vascular access in diabetic patients: an audit. *Nephrol Dial Transplant* 2000; **15**:1317–1325.
- 6 BONFORTE G, ZERBI S, SURIAN M. The middle-arm fistula: a new native arteriovenous vascular access for hemodialysis patients. *Ann Vasc Surg* 2004; **18**(4):448–452.
- 7 BENDER MH, BRUYNINCKX CM, GERLAG FG. The Gracz arteriovenous fistula evaluated. Results of the brachiocephalic elbow fistula in haemodialysis angio-access. *Eur J Vasc Endovasc Surg* 1995; **10**(3):294–297.
- 8 ZEEBREGTS CJ, TIELLIU IFJ, HULSEBOS RG, DE BRUIN C, VERHOEVEN ELG, HUISMAN RM *et al.* Determinants of failure of brachiocephalic elbow fistulas for haemodialysis. *Eur J Vasc Endovasc Surg* 2005; **30**(2):209–214.

- 9 DUNLOP MG, MACKINLAY JY, JENKINS AM. Vascular access: experience with the brachiocephalic fistula. *Ann R Coll Surg Engl* 1986;**68**:203–206.
- 10 ZIBARI GB, ROHR MS, LANDRENEAU MD, BRIDGES RM, DEVULT GA, PETTY FH *et al.* Complications from permanent hemodialysis vascular access. *Surgery* 1988;**104**:681–686.
- 11 NAZZAL MM, NEGLEN P, NASEEM J, CHRISTENSON JT, AL-HASSAN HK. The brachiocephalic fistula: a successful secondary vascular access procedure. *VASA* 1990;**19**(4):326–329.
- 12 MURPHY GJ, SAUNDERS R, METCALFE M, NICHOLSON ML. Elbow fistulas using autogeneous vein: patency rates and results of revision. *Postgrad Med J* 2002;**78**(922):483–486.
- 13 LOK CE, OLIVER MJ, SU J, BHOLA C, HANNIGAN N, JASSAL SV. Arteriovenous fistula outcomes in the era of the elderly dialysis population. *Kidney Int* 2005;**67**(6):2462–2469.
- 14 DAGHER F, GELBER R, RAMOS E, SADLER J. The use of basilic vein and brachial artery as an A–V fistula for long term hemodialysis. *J Surg Res* 1976;**20**(4):373–376.
- 15 RIVERS SP, SCHER LA, SHEEHAN E, LYNN R, VEITH FJ. Basilic vein transposition: an underused autologous alternative to prosthetic dialysis angioaccess. *J Vasc Surg* 1993;**18**:391–397.
- 16 HOSSNY A. Brachio basilic arteriovenous fistula: different surgical techniques and their effects on fistula patency and dialysis-related complications. *J Vasc Surg* 2003;**37**:821–826.
- 17 COBURN MC, CARNEY Jr WI. Comparison of basilic vein and polytetrafluoroethylene for brachial arteriovenous fistula. *J Vasc Surg* 1994;**20**:896–904.
- 18 EL MALLAH S. Staged basilic vein transposition for dialysis angioaccess. *Int Angiol* 1998;**17**(2):65–68.
- 19 HUMPHRIES Jr AL, COLBORN GL, WYNN JJ. Elevated basilic vein arteriovenous fistula. *Am J Surg* 1999;**177**(6):489–491.
- 20 MURPHY GJ, NICHOLSON ML. Autogeneous elbow fistulas: the effect of diabetes mellitus on maturation, patency, and complication rates. *Eur J Vasc Endovasc Surg* 2002;**23**(5):452–457.
- 21 SEGAL JH, KAYLER LK, HENKE P, MERION RM, LEAVEY S, CAMPBELL Jr DA. Vascular access outcomes using the transposed basilic vein arteriovenous fistula. *Am J Kidney Dis* 2003;**42**(1):151–157.
- 22 TAGHIZADEH A, DASGUPTA P, KHAN MS, TAYLOR J, KOFFMAN G. Long-term outcomes of brachio basilic transposition fistula for haemodialysis. *Eur J Vasc Endovasc Surg* 2003;**26**(6):670–672.
- 23 RAO RK, AZIN GD, HOOD DB, ROWE VL, KOHL RD, KATZ SG *et al.* Basilic vein transposition fistula: a good option for maintaining hemodialysis access site options? *J Vasc Surg*. 2004;**39**(5):1043–1047.
- 24 BAZAN HA, SCHANZER H. Transposition of the brachial vein: a new source for autologous arteriovenous fistulas. *J Vasc Surg* 2004;**40**:184–186.
- 25 HUBER TS, CARTER JW, CARTER RL, SEEGER JM. Patency of autogenous and polytetrafluoroethylene upper extremity arteriovenous hemodialysis accesses: a systematic review. *J Vasc Surg* 2003;**38**:1005–1011.
- 26 PIERRE-PAULI D, WILLIAMS S, LEE T, GAHTAN V. Saphenous vein loop to femoral artery arteriovenous fistula: a practical alternative. *Ann Vasc Surg* 2004;**18**:1615–594718.
- 27 GRADMAN WS, LAUB J, COHEN W. Femoral vein transposition for arteriovenous hemodialysis access: improved patient selection and intraoperative measures reduce postoperative ischemia. *J Vasc Surg* 2005;**41**:279–284.
- 28 HAZINEDAROGLU SM, TUZUNER A, AYLI D, DEMIRER S, DUMAN N, YERDEL MA. Femoral vein transposition versus femoral loop grafts for hemodialysis: a prospective evaluation. *Transplant Proc* 2004;**36**(1):65–67.

Accepted 7 October 2005

Available online 16 November 2005