

## EDUCATIONAL ARTICLE

# Vascular Access in Children: The Importance of Microsurgery for Creation of Autologous Arteriovenous Fistulae

P. Bourquelot\*

*Access Surgeon, Clinique Jouvenet, Paris, France*

*Microsurgery gives much better immediate and long term results than classical surgery for the creation of direct arteriovenous fistulae, the best chronic access to blood in children.*

*Keywords: Angioaccess; Arteriovenous fistula; Child; Microsurgery; Hemodialysis.*

### Introduction

First described by Brescia and Cimino in 1966<sup>1</sup>, the autologous arteriovenous fistula (AVF) was soon considered as the best form of haemodialysis angioaccess in adults. In children the first publications<sup>2–4</sup> indicated 50% immediate failure due to small vessels, often reduced by spasm provoked by arterial dissection. In 1960, Jacobson and Suarez achieved the first vascular microanastomosis on 1 mm diameter vessels. When applied to AVF creation in children, microsurgery provides a dramatic benefit. Other forms of angioaccess may have deleterious effects on children: central venous catheters (CVC) may cause central vein stenosis and thrombosis precluding further AVF formation and arteriovenous grafts (AVG) have very poor patency in children. Finally renal transplantation may not last a lifetime. For children with access created for diseases other than end-stage renal disease the microsurgical creation of an AVF is also a safe and durable alternative to peripheral venipuncture and CVC.

### Microsurgical Technique

Preservation of the veins is essential in every child requiring haemodialysis. Whenever possible, the dorsal veins of the hand must be used for blood sampling.

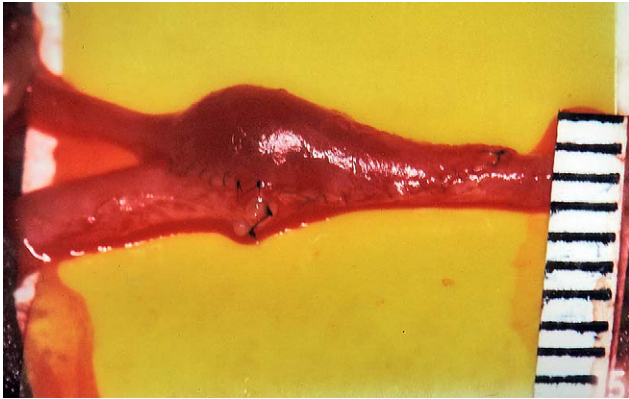
Absolute protection of the non-dominant arm is necessary. Subclavian CVCs, which have a high risk of upper limb proximal vein stenosis, should be prohibited. The condition of the vein is assessed by careful preoperative clinical examination; a duplex scan is necessary if there is any doubt, particularly in very young children; venous angiography is mandatory in patients who have previously had a CVC. A prophylactic broad spectrum antibiotic is prescribed. The rules for suturing are that forceps must never grasp the intima, the adventitia is incised and not resected, high pressure clamps must be avoided, and the thinnest possible needles are to be used. Preventive haemostasis using a pneumatic tourniquet<sup>5</sup> makes extensive arterial dissection for clamping unnecessary: arterial spasm is avoided. When prophylactic haemostasis is incomplete, microclamps are placed on the artery after minimal dissection. Anticoagulation is mandatory in hypercoagulation conditions (mainly nephrotic syndrome). The equipment needed includes: ophthalmologic scissors, microsurgical needle holders, disposable ophthalmologic scalpel, Dumont forceps, single and double Acland clamps, heparinized saline, surgical microscope with two facing binoculars, Ethilon 9–10/0 (BV70 and BV50) sutures.

*Radial-to-cephalic arteriovenous fistulas<sup>6</sup> (Figs. 1 & 2)*

The incision is longitudinal, half way between the cephalic vein and the radial artery in the wrist. The nerves must be carefully preserved. The vein is freed, a ligature being placed on the collateral branches avoiding electric coagulation that could damage the vascular trunk

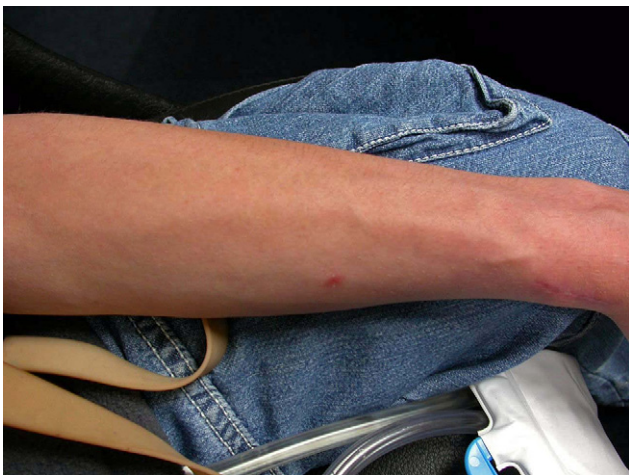---

Update on Renal Access and Transplantation – one of a series of educational articles edited by Mr Christopher Gibbons, Swansea, UK.  
\*Corresponding author. Dr. Pierre Bourquelot, MD, Vascular Surgeon, Clinique Jouvenet, Paris, France.  
E-mail address: [pbourquelot@sfav.org](mailto:pbourquelot@sfav.org)



**Fig. 1.** Completed microsurgical radiocephalic anastomosis in an infant.

itself. Saline irrigation must be frequent in order to prevent drying, and vessels are only handled by the adventitia. After section of the vein above a ligature, a longitudinal posterior incision of approximately 10 mm in length is made in the proximal vein. The anterior wall of the artery is exposed. A longitudinal arteriotomy is made with a disposable ophthalmologic scalpel and completed with scissors. If a few drops of blood appear they are rinsed with heparin saline and dried with small sponges. The anastomosis is constructed with four running sutures, by suturing first the proximal angle. The running suture is left loose at the beginning so as to leave the lumen open. Frequent use of the zoom facilitates this very precise part of the operation and the needle must be repositioned in the needle holder for each passage through a vessel. Both proximal running sutures (posterior and anterior) are stopped at the middle of the arteriotomy. The anastomosis is then completed, starting from the distal angle. The tourniquet is then released. If there is a leak, an



**Fig. 2.** Functioning radiocephalic AV fistula in a 13 year old child, one month post-operatively.

additional suture is added. Patency is confirmed by Doppler ultrasound, as the murmur can be absent during the first postoperative hours, particularly in small children. It is very important to ascertain that the vein is not stenosed at the upper limit of the dissection.

#### *Variations*

**One running suture anastomosis:** The proximal suture is performed first, starting at the middle of the posterior wall of the arteriotomy, proceeding to the proximal angle, and down to the middle of the anterior wall. The distal suture is then completed. This technique gives excellent vision of the arterial lumen.

It may be necessary to surgically transpose the vein subcutaneously 2 months later in small children with thick subcutaneous tissue.

#### *Ulnar-to-basilic arteriovenous fistulas*

A sufficient length of the vein must be freed, as it is situated at a distance from the artery. It can be helpful to place the forearm in flexion at the elbow during dissection. The artery is approached by partial excision of the flexor carpi ulnaris. The interval before puncture is longer than with a radial-to-cephalic AVF.

#### *Brachial-to-cephalic arteriovenous fistulas*

A transverse incision at the anterior aspect of the elbow exposes the medial branch of the cephalic vein, which must be sufficiently freed to allow it to come into proximity with the brachial artery without traction. Here again, using a pneumatic tourniquet avoids having to free the artery.

#### *Variations*

Anastomosis between the brachial artery and the cephalic vein by means of the medial branch of the basilic vein is preferable. This will be perfused backwards in the absence of valves. Both vessels, which follow almost superimposed routes, are approached by a short antecubital incision. The vein is divided as high as possible and, after minimal dissection, its lower segment is anastomosed to the brachial artery. It is essential to ligate the perforating antecubital vein to avoid the risk of high flow with cardiac overload. Ligation of the upper part of the forearm cephalic vein is also necessary to avoid the risk of retrograde perfusion of the forearm, which would impair venous drainage of the hand. Both these risks mean that retrograde AVF and side to side AVF at the elbow must not be used.

*Brachial-to-basilic arteriovenous fistulas with subcutaneous transposition*

The basilic vein follows a route which rapidly becomes deep above the elbow, meaning that it is often undamaged. Its use for angioaccess necessitates surgical transposition, even in the thinnest children. Its transposition is much easier when it is performed during a second stage, the first consisting of a simple AVF at the elbow which results in dilatation of the vein and thickening of its walls. The initial AVF is constructed using the medial branch of the basilic vein at the elbow or, if necessary, on its lateral branch. Transposition performed 2 months later requires a longitudinal incision on the medial side of the upper arm. Collaterals of the veins are ligated and divided. The vein is tunnelled very superficially along a straight line. Reimplantation on the artery is performed as low as possible. An interval of 3 weeks must be left before puncturing.

*Femoral-to femoral arteriovenous fistulas, with transposition*

This type of vascular access is rarely used. Superficial transposition of the femoral vein is usually in a straight line with an anastomosis on the distal superficial femoral artery.

*Arteriovenous bridge-graft*

In this case a graft (biograft or PTFE) is implanted between an artery and a vein. It is located under the skin in such a way as to be accessible to puncture.

### The Results of Microsurgical AVF Creation

*With microsurgery*

Our first experience for AVF in 32 children (Table 1) was reported in 1978 (Coulonges S, Thèse de

**Table 1. Arteriovenous angioaccesses in children: major publications**

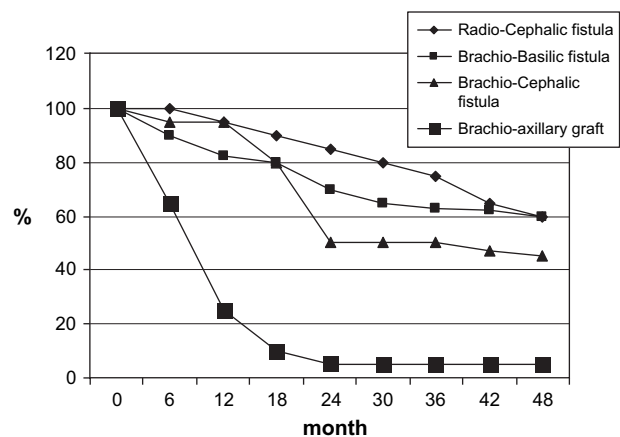
	Bourquelot <sup>8</sup>	Sanabia <sup>10</sup>	Lumsden <sup>14</sup>	Bagolan <sup>11</sup>	Sheth <sup>15</sup>
Year of publication	1990	1993	1994	1998	2002
Country	France	Spain	USA	Italy	USA
Microsurgery	yes	yes	no	yes	no
Number of accesses	434	86	61	112	52
Failing to mature AVF	10%	10%	30%	5%	33%
AVF vs. Graft	93%	100%	24%	100%	46%

Médecine, Université Pierre et Marie Curie Paris VI) and we published our first results for AVF microsurgery in children under 10 kg in 1981.<sup>7</sup>

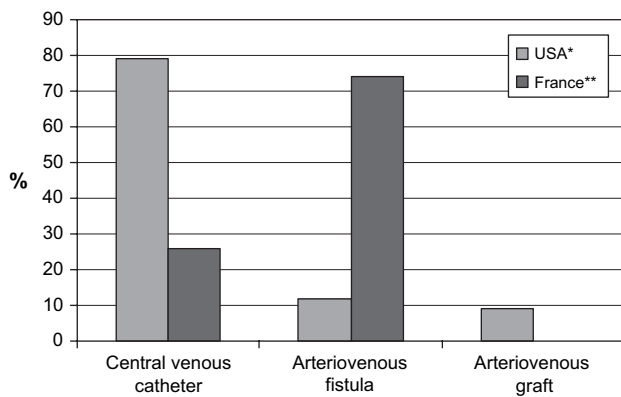
In 1990<sup>8</sup> we reported 380 children undergoing microsurgery for AVF: the percentage of autologous AVF versus grafts was 93% and the creation of a distal AVF was possible in 78% of the children. The immediate patency rate was 96% and the 24-month patency rate was 85% in distal radial-cephalic AVF, 72% in brachial-basilic AVF, 47% in brachial-cephalic AVF and only 5% in AV bridge-grafts (Fig. 3).

These benefits of microsurgery for children have been emphasized by a Canadian group<sup>9</sup> in 1984, by Spanish workers in 1993<sup>10</sup> and by an Italian team in 1998.<sup>11</sup>

In a transverse survey of the three paediatric nephrology departments in Paris on 1 February 2003, we observed that 70% of 33 ESRD children were being haemodialyzed via an autologous fistula, 24% via a jugular CVC, and 6% were on peritoneal dialysis. This compared favourably with the annual publication of the North American Pediatric Renal Transplant Cooperative (NAPRTC) Study in 1996<sup>12</sup> reporting that between 1 January 1992 and 16 January 1996 two-thirds of children and adolescents on dialysis were maintained on peritoneal dialysis, despite an overall peritonitis rate of one episode every 13 patient-months, the majority of haemodialysis accesses were external percutaneous catheters (Fig. 4), with the subclavian vein the most common site. More recently the publication of NAPRTC in 2003<sup>13</sup> reported that, between 1992 and 1998, 70 to 80% of children and 59% of adolescents on dialysis were maintained on peritoneal dialysis and that younger children received haemodialysis almost exclusively through percutaneous catheters, while 57% of children more than six years



**Fig. 3.** Angioaccesses in children – Long term patency (N = 434).



**Fig. 4.** Percentages of central venous catheter vs. arteriovenous access in American and French children. (\*: 2001 NAPRTCS report, \*\*: Paris 01/02/2003)

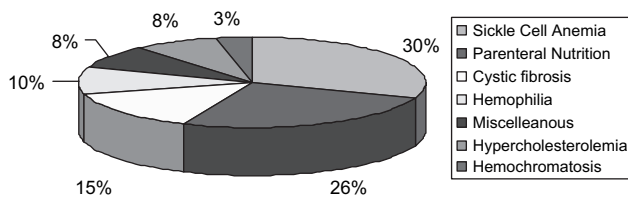
old were dialyzed with fistula or graft after six months on haemodialysis.

In 2001, we retrospectively reviewed 69 AVF in a young (mean age 20 years) and difficult cohort of 64 non-renal chronic disease patients requiring a permanent angioaccess for repeated transfusions, perfusions, apheresis and drug injections for sickle cell anaemia (N = 19), parenteral nutrition (N = 16), cystic fibrosis (N = 9), haemophilia (N = 6), hypercholesterolemia (N = 5), haemochromatosis (N = 3), and miscellaneous conditions (N = 6) (Fig. 5). Although there had been no previous venous preservation strategy, it was possible with microsurgery to create distal AVF in 68% of cases; and insertion of a graft was necessary in only 4%. Long-term patency rate was around 60% after 10 years (Fig. 6).

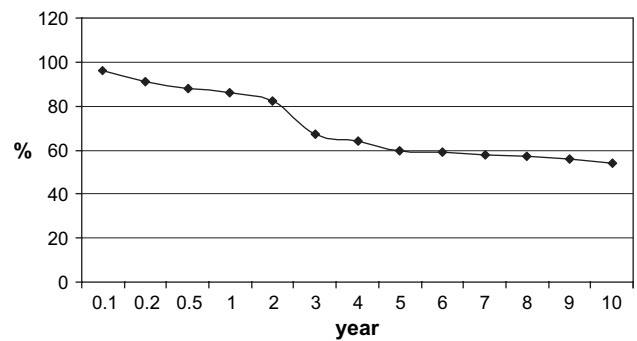
*Without microsurgery*

Limited-quality arteriovenous fistulas are frequently observed (Table 1). Proximal fistulas and grafts are easier to construct in children but they have high complication rates and they will destroy proximal veins and therefore threaten the long-term survival of the patient.

In 1994, Lumdsen reported on 61 angioaccesses in children without microsurgery; mean age was 11



**Fig. 5.** Arteriovenous fistula in non-ESRD patients – Different pathologies.



**Fig. 6.** Long-term patency of autologous arteriovenous fistulas in 64 non-renal chronic disease young patients.

years, only 25% were simple AVF and 30% of them failed to mature.<sup>14</sup> The mean functional patency was 6.2 months; 76% of the accesses were grafts, mostly in the upper arm or in the thigh, with a mean patency of 10 months.

In 2002, Sheth<sup>15</sup> reported on 52 arteriovenous angioaccesses in 13-year-old (mean age) children. The percentage of autologous AVF was low (46%) and the percentage of primary failures (failed to mature) was high (33%).

Curiously, these two authors demonstrated no interest in microsurgery and made no reference to any of the previous publications concerning microsurgical creation of AVF in children. Furthermore, Sheth stated wrongly that ‘the literature contains very little data regarding the success of permanent vascular access in paediatric patients’. In fact, the three European surgical teams who used microsurgery for angioaccesses in children (Table 1) reported only 5 to 10% percent of fistulas that failed to mature and 0 to 14% percent of grafts versus AVF. These results compare favourably with those of the two American teams not using microsurgery; 30 and 33% of their AVF failed to mature and 76 to 54% were grafts.

In 2005, Ramage<sup>16</sup> published the results of a 20-year retrospective study without the use of microsurgery. One hundred twenty two arteriovenous vascular access procedures were performed on children, with a median age at initial access formation of 12.0 years (range, 4 weeks to 21.9 years). The most common procedure was CVC insertion (182 procedures) and then AVF formation (107 procedures), with only 15 AVGs created. Median censored survival was 3.14 years (95% confidence interval, 1.22 to 5.06) for AVFs and 0.6 years (95% confidence interval, 0.20 to 1.00) for CVCs. Factors adversely affecting vascular access survival were younger age, trainee operator, presence of hypoalbuminemia, and type of access undertaken, with AVF better than CVC.

### Summary

- Microsurgery is a prerequisite for creation of angioaccess in children. It includes the use of a surgical microscope, microsurgical instruments, prophylactic haemostasis and no-touch surgery.
- In the recent publications, the percentages of arteriovenous fistulas versus grafts varied from 46 to 34% without microsurgery, and from 100 to 86% with microsurgery. Likewise, the percentages of AVF which failed to mature varied from 30 to 33% without microsurgery, and from 5 to 10% with microsurgery.
- Good results of microsurgically created AVF partly explain the high percentage of end-stage renal disease (ESRD) children treated by haemodialysis in Paris using an autologous fistula (70% of 33 children), while only 24% were haemodialyzed via a central venous catheter and 6% were on peritoneal dialysis.
- Microsurgical AVF are also created successfully in children requiring frequent blood access for various non-ESRD chronic diseases. We were able to create a distal AVF in 68% of cases and the long-term patency rate was just below 60% after 10 years.

### References

- 1 BRESCIA MJ, CIMINO JE, APPEL K, HURWICH BJ. Chronic hemodialysis using venipuncture and a surgically created arteriovenous fistula. *N Engl J Med* 1966;**275**:1089–1092.
- 2 SICARD GA, MERRELL RC, ETHEREDGE EE, ANDERSON CB. Subcutaneous arteriovenous dialysis fistulas in pediatric patients. *Trans Am Soc Artif Intern Organs* 1978;**24**:695–698.
- 3 BROYER MLC, GAGNADOUX M, CUKIER J, BEURTON D, VACANT J. 'By-pass' et fistule artério-veineuse en vue de l'hémodialyse chronique chez l'enfant. *Arch Fr Pédiatr* 1973;**30**:145–161 [in French].
- 4 GAGNADOUX MF, PASCAL P, BOURQUELOT P *et al.* L'abord vasculaire chez l'enfant traité par hémodialyse chronique. *Néphrologie* 1978;**12**:935–944 [in French].
- 5 BOURQUELOT P. Preventive haemostasis with an inflatable tourniquet for microsurgical distal arteriovenous fistulas for haemodialysis. *Microsurgery* 1993;**14**:462–463.
- 6 MERIA PC, STOLBA J, RAYNAUD F, BOURQUELOT P. Création des abords vasculaires pour hémodialyse. *Encycl Méd Chir* 1995;**41**–100:12p.
- 7 BOURQUELOT P, WOLFELER L, LAMY L. Microsurgery for haemodialysis distal arteriovenous fistulae in children weighing less than 10 kg. *Proc Eur Dial Transplant Assoc* 1981;**18**:537–541.
- 8 BOURQUELOT P, CUSSENOT O, CORBI P *et al.* Microsurgical creation and follow-up of arteriovenous fistulae for chronic haemodialysis in children. *Pediatr Nephrol* 1990;**4**:156–159.
- 9 YAZBECK S, O'REGAN S. Microsurgery for Brescia-Cimino fistula construction in pediatric patients. *Nephron* 1984;**38**:209–212.
- 10 SANABIA J, POLO JR, MORALES MD, CANALS MJ, POLO J, SERANTES A. Microsurgery in gaining paediatric vascular access for haemodialysis. *Microsurgery* 1993;**14**:276–279.
- 11 BAGOLAN P, SPAGNOLI A, CIPRANDI G *et al.* A ten-year experience of Brescia-Cimino arteriovenous fistula in children: technical evolution and refinements. *J Vasc Surg* 1998;**27**:640–644.
- 12 LERNER GR, WARADY BA, SULLIVAN EK, ALEXANDER SR. Chronic dialysis in children and adolescents. The 1996 annual report of the North American Pediatric Renal Transplant Cooperative Study. *Pediatr Nephrol* 1999;**13**:404–417.
- 13 LEONARD MB, DONALDSON LA, HO M, GEARY DF. A prospective cohort study of incident maintenance dialysis in children: an NAPRTC study. *Kidney Int* 2003 Feb;**63**(2):744–755.
- 14 LUMSDEN AB, MACDONALD MJ, ALLEN RC, DODSON TF. Hemodialysis access in the pediatric patient population. *Am J Surg* 1994;**168**:197–201.
- 15 SHETH RD, BRANDT ML, BREWER ED, NUCHTERN JG, KALE AS, GOLDSTEIN SL. Permanent hemodialysis vascular access survival in children and adolescents with end-stage renal disease. *Kidney Int* 2002;**62**:1864–1869.
- 16 RAMAGE IJ, BAILIE A, TYERMAN KS, MCCOLL JH, POLLARD SG, FITZPATRICK MM. Vascular Access Survival in Children and Young Adults Receiving Long-Term Hemodialysis. *Am J Kidney Dis* 2005;**45**:708–714.

Accepted 26 April 2006

Available online 6 June 2006