

EDUCATIONAL SERIES ON THORACIC AORTA (EDITED BY R. FATTORI)

Indication, Timing and Results of Endovascular Treatment of Type B Dissection

I. Akin^a, S. Kische^a, H. Ince, C.A. Nienaber*

Department of Medicine, Division of Cardiology, University Hospital Rostock, Rostock School of Medicine, Ernst-Heydemann-Str. 6, 18057 Rostock, Germany

Submitted 9 December 2008; accepted 11 December 2008
Available online 25 January 2009

KEYWORDS

Aortic dissection;
Long-term follow-up;
Malperfusion;
Stent graft;
Timing

Abstract Aortic dissection is an uncommon but a highly lethal condition. Dissection of the ascending aorta is associated with a mortality rate of 1–2% per hour within the first 24 h and should be managed by an open surgery. An uncomplicated, acute, type B dissection, which should be treated medically, is less frequently lethal, with survival rates of 84% within 1 year. Unfortunately, long-term outcome of medical therapy alone is suboptimal, with a reported 30–50% mortality rate at 5 years and a delayed expansion of the false lumen in 20–50% of patients at 4 years. In this setting, endovascular treatment should be considered when the aortic diameter exceeds 55–60 mm, in case of uncontrolled pain, blood pressure and rapid growth of the dissecting aneurysm (>1 cm per year). About 30–42% of acute, type B aortic dissections are complicated, as evidenced by haemodynamic instability or peripheral vascular ischaemia with a mortality rate of 50–85% if not treated properly. In this scenario, stent-graft repair is an attractive alternative to surgical repair for correcting ischaemic complications. The long-term therapy of patients with aortic dissection includes aggressive medical therapy, follow-up visits and serial imaging.

© 2009 European Society for Vascular Surgery. Published by Elsevier Ltd. All rights reserved.

Aortic dissection is an uncommon but a highly lethal condition, with an estimated incidence ranging from 3 to 8 cases per 100,000 persons.^{1–3} Approximately, 0.5% of patients presenting to an emergency department with chest or back pain suffer from aortic dissection or its

precursors.⁴ Men are twice as often found to suffer from acute aortic dissection than women, with 60% of dissection cases classified as proximal or type A and 40% as distal or type B according to the Stanford classification.¹ The historical data of untreated aortic dissection of the ascending aorta show a mortality rate of 1–2% per hour within the first 24 h, resulting in a mortality rate of up to 50–74% within the first 2 weeks.^{1,2} An uncomplicated, acute, type B dissection is less frequently lethal, with survival rates of 89% in medically treated patients at 1 month, 84% within 1 year and up to 80% within 5 years.^{1,5}

* Corresponding author. C.A. Nienaber, Tel.: +49 (0)381 494 77 03; fax: +49 (0)381 494 77 02.

E-mail address: christoph.nienaber@med.uni-rostock.de (C.A. Nienaber).

^a Both authors contributed equally to this manuscript.

However, patients with acute or late complications, including renal failure, visceral ischaemia or contained rupture, often require urgent repair, with a mortality rate mounting to 20% at day 2, and 25–50% within 1 month.¹ Similar to type A dissection, advanced age, rupture, shock and malperfusion are important independent predictors of early mortality in type B dissection.^{6,7} While almost every patient with a type A dissection should be managed by open surgery, endovascular concepts have emerged as an alternative therapeutic option to manage acute and chronic aortic dissections, mainly distal thoracic aortic dissection. For proximal or type A dissection, any endovascular approach remains experimental and anecdotal for localised pathologies in patients unfit for surgical therapy. Although dissection of the aorta is an acute event, in most cases, an underlying chronic and generalised disease of the media vessel wall predisposes the aorta to chronic alterations, eventually leading to dissection.

In this article, we review current indication, timing and results of endovascular management of patients with type B aortic dissection in the context of the recent literature.

Indication for Stent-graft Repair in Type B Aortic Dissection

The natural course of aortic dissection is determined by two elements: early complications and chronic events. Early complications comprise any kind of malperfusion syndrome or rupture, while late events are usually a continued false lumen expansion with the risk for late rupture. Once a patient survives the first 2 weeks after the impact of dissection, the process is defined as chronic. Acute and chronic dissections differ considerably with respect to medical treatment, taking into consideration that even acute dissections can be complicated or uncomplicated.

The feasibility of stent grafting of the descending thoracic aorta has already been established as an alternative to surgical treatment of type B aortic dissection. However, due to the lack of both randomised controlled trials with long-term follow-up data and randomised comparisons with medical and surgical techniques, the indications for endovascular strategies remain to be fully defined for dissection (Table 1). There is clear observational evidence that depressurisation and shrinkage of the false lumen are beneficial in acute dissection, ideally followed by complete thrombosis of the false lumen and remodelling of the entire dissected aorta. Similar to previously accepted indications for surgical intervention, scenarios such as intractable pain, rapidly expanding false lumen, diameter >55 mm and signs of imminent rupture or distal malperfusion are increasingly being accepted as indications for stent-graft placement in type B dissection.^{8,9} Even in some cases of retrogradely extended type A dissections, stent-graft treatment of the descending thoracic aorta can also be performed as a single step or as two steps after initial surgical repair of the proximal part of the aorta or the arch. Open surgery may include an elephant trunk or transposition of arch vessels to allow optimal landing zones for endovascular completion in a hybrid approach. In case of retrograde type A dissection, an isolated distal-entry tear can sometimes be sealed by

Table 1 Distribution of differential therapeutic strategies in aortic dissection

<i>Surgery</i>
Type A aortic dissection
Acute type B dissection complicated by
Retrograde extension into the ascending aorta
Dissection in fibrillinopathies (e.g., Marfan's syndrome, Ehlers–Danlos syndrome)
<i>Medical</i>
Uncomplicated, acute type B dissection
Stable, isolated aortic arch dissection
Chronic type B dissection
<i>Interventional</i>
Unstable, acute type B dissection
Malperfusion
Rapid expansion (>1 cm per year)
Critical diameter (≥ 5.5 cm)
Refractory pain
Stable type B dissection (under evaluation)
Type B dissection with retrograde extension into the ascending aorta
Hybrid procedure for extended type A aortic dissection

a stent graft, hence enabling thrombosis and remodelling even of the proximal false lumen in type A dissection. With endografting, paraplegia generally appears to be a rare phenomenon (0.8%), but is known to be associated with extensive coverage of the aorta exceeding 20 cm and with the use of multiple stent grafts, or in case of previously operated aortas.¹⁰

Stable, Acute, Type B Aortic Dissection

Patients with suspected acute aortic dissection should be admitted to the intensive care unit for prompt diagnostical evaluation under clinical and haemodynamic monitoring. Reduction of systolic blood pressure to 100–120 mm Hg, with an eye on the renal function and pain relief, is the initial priority and is achieved by morphine sulphate and intravenous beta-blocking agents (e.g., metoprolol, esmolol or labetalol) or by a combination with vasodilating drugs such as sodium nitroprusside, at a dose of $0.3 \mu\text{g kg}^{-1} \text{min}^{-1}$, or angiotensin-converting enzyme inhibitors. Intravenous verapamil or diltiazem may also be used, if beta-blocking agents are contraindicated. A monotherapy with beta-blocking agents may be adequate to control mild hypertension (Table 2). In addition, heart rate should be kept low – a heart rate below 60 bpm significantly decreases secondary adverse events (aortic expansion, recurrent aortic dissection, aortic rupture and/or need for aortic surgery) in type B aortic dissection compared to a conventional rate of more than 60 bpm.¹¹ Once both stable blood pressure and symptom relief are achieved, the patient with an acute, uncomplicated, type B aortic dissection can be discharged (usually within 14 days), and clinical and imaging follow-up should be offered and advised at 3 and 6 months and annually thereafter. In a series of 384 patients with type B dissections from the International Registry of

Table 2 Initial medical treatment in aortic dissection

Name	Mechanism	Dose	Cautions/contraindications
Esmolol	Cardioselective beta-1 blocker	Load: 500 $\mu\text{g kg}^{-1}$ IV Drip: 50 $\mu\text{g kg}^{-1} \text{min}^{-1}$ IV Increase by increments of 50 $\mu\text{g min}^{-1}$	Asthma or bronchospasm Bradycardia 2nd- or 3rd-degree AV block Cocaine or methamphetamine abuse
Labetalol	Non-selective beta-1,2 blocker Selective alpha-1 blocker	Load: 20 mg IV Drip: 2 mg min^{-1} IV	Asthma or bronchospasm Bradycardia 2nd- or 3rd-degree AV block Cocaine or methamphetamine abuse
Enalaprilat	ACE inhibitor	0.625–1.25 mg IV q 6 h Max dose: 5 mg q 6 h	Angio-oedema Pregnancy Renal artery stenosis Severe renal insufficiency
Nitroprusside	Direct arterial vasodilator	Begin at 0.3 $\mu\text{g kg}^{-1} \text{min}^{-1}$ IV. Max dose 10 $\mu\text{g kg}^{-1} \text{min}^{-1}$	May cause reflex tachycardia Cyanide/thiocyanate toxicity – especially in renal or hepatic insufficiency
Nitroglycerin	Vascular smooth muscle relaxation	5–200 $\mu\text{g min}^{-1}$ IV	Decreases preload – contraindicated in tamponade or other preload-dependent states Concomitant use of sildenafil or similar agents

Acute Aortic Dissection (IRAD), 73% were managed medically with an in-hospital mortality of 10%.^{1,7,12} The short-term survival rates were 91% at 1 month and 89% at 1 year. The reported long-term survival rate with medical therapy varies between 60% and 80% at 4–5 years and is around 40–45% at 10 years.^{1,2,7,12} Yet again, the predictors of early mortality were malperfusion, hypotension, lack of chest or abdominal pain and partial thrombosis of the false lumen.^{7,13}

Unstable, Acute, Type B Aortic Dissection

About 30–42% of the acute type B aortic dissections are complicated, as evidenced by haemodynamic instability or peripheral vascular ischaemia.¹² In contrast to the previously described stable, acute dissection, unstable patients have a highly unpredictable outcome. Among other complications, acute lower limb and visceral ischaemia have been reported in 30–50% of patients; malperfusion syndrome occurs frequently in cases of distally extended dissections and may lead to death in 50–85% of patients if not treated properly.^{5,14,15} In a necropsy study of 18 patients with type B dissection, a compression of the true aortic lumen with aortic obstruction was evident in 56% of patients.¹⁶ One mechanism of malperfusion may be the result of either static extension of the dissection flap directly into the orifice of a visceral or lower-limb artery, thereby narrowing its lumen, or of a dynamic obstruction of the vessel by means of the flap prolapsing into the vessel

origin. Once diagnosed, these complications require emergent therapeutic action. However, despite a wide array of open surgical strategies, operative mortality rate for patients with acute aortic dissection, complicated by

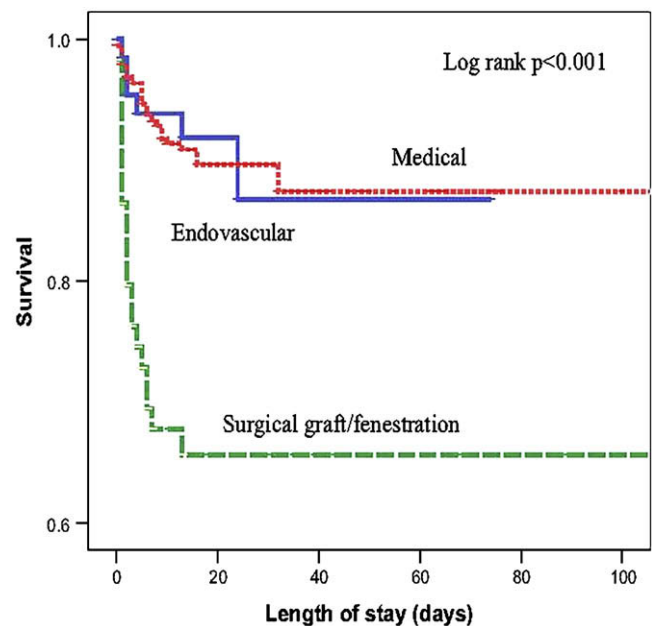


Figure 1 Comparison of medical, surgical and endovascular treatment in patients with acute type B aortic dissection.²¹

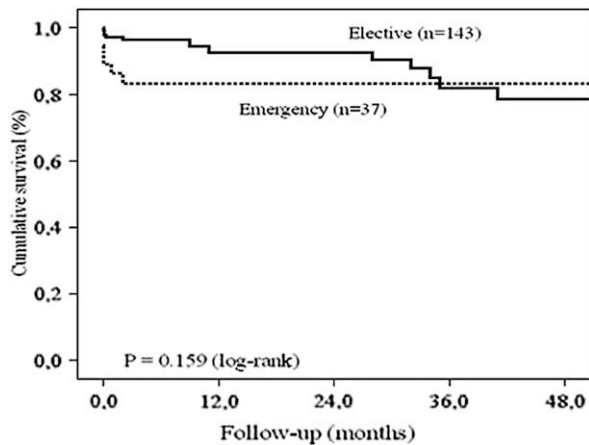


Figure 2 Comparison of elective- and emergency-treated patients with type B aortic dissection. Data from the TTR registry.⁴⁸

renal ischaemia, has been reported as high as 50%, and even 88% when mesenteric perfusion is impaired.^{17–20} Fattori et al. compared the impact on survival of different treatment strategies in 571 patients with acute type B aortic dissection.²¹ Of the 571 patients with acute type B aortic dissection, 390 (68.3%) were treated medically; among the complicated cases, 59 (10.3%) underwent standard open surgery and 66 (11.6%) were subjected to an endovascular approach. The in-hospital mortality was significantly higher after open surgery (33.9%) than after endovascular treatment (10.6%; $p = 0.002$) for those patients with complicated type B aortic dissection (Fig. 1). Thus, stent-graft repair is an attractive alternative to surgical repair for correcting ischaemic complications (Fig. 2)⁴⁸. Usually, stent-graft occlusion of the entry site in

the descending thoracic aorta results in thrombosis of the false lumen and predominant flow in the true lumen, thus normalising distal-vessel perfusion and restoring branch-vessel patency²² (Fig. 3). The PETTICOAT (provisional extension to induce complete attachment) concept takes the idea even further by extending the stent-graft scaffold distally with open-cell bare-metal stents. For instance, if malperfusion persists after coverage of the primary entry tear, additional distal open stents are the devices deployed until distal malperfusion is corrected.²³ With this concept, aortic fenestration manoeuvres or branch-vessel re-vascularisation with uncovered stent are usually not needed and almost obsolete.

The EUROSTAR/United Kingdom registry report represents a first large series of patients treated with thoracic aortic stent grafts; in this combined registry, 131 patients with aortic dissection (5% proximal, 81% distal and 14% not classified) were treated with stent grafts, with 57% of patients presenting with symptoms of rupture, aortic expansion or side-branch occlusion. Although meaningful long-term data are still lacking, primary technical success was achieved in 89% of patients, at the expense of a 30-day mortality rate of only 8.4%.²⁴ A series of patients at the Arizona Heart Institute, comprising 40 patients (23 acute and 17 chronic) treated with a thoracic endograft for complicated, distal, aortic dissection, enjoyed a technical success rate of 95%. There was one peri-operative death due to iliac rupture and one case of paraplegia, while 15 patients (38%) experienced transient postoperative complications, mostly renal and pulmonary, the 1-year survival rate was 85%. Of the patients available for follow-up computed tomography (CT), 97% (30 of 31 patients) exhibited a stable or decreasing aortic diameter and no rupture occurred during the observational period, therefore justifying the conclusion that thoracic aortic stent grafting obviously stabilised the aorta and decreased the

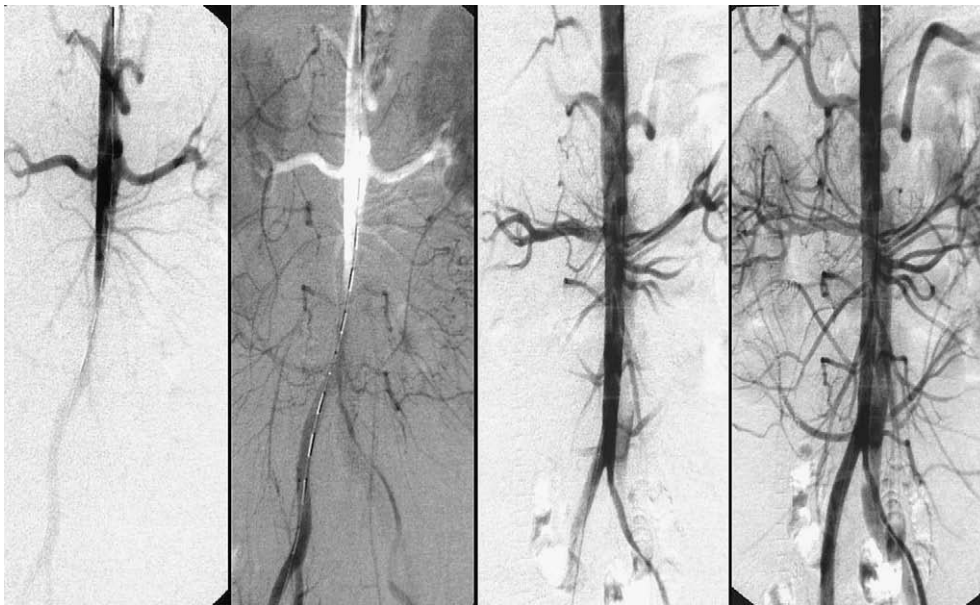


Figure 3 Malperfusion of distal aorta by occlusive type B dissection. Stent-graft placement in the true lumen of the proximal descending aorta re-established flow to the abdomen and legs.

Table 3 Results of endovascular stent-graft implantation in different clinical conditions

Author	Year	n	Technical success (%)	Paraplegia (%)	Mortality (%)	Follow-up (month)
<i>Acute complicated type B dissection</i>						
Beregi ⁸	2003	46	96	n.a.	17	8
Bortone ⁴⁵	2004	43	100	0	7	21
Leurs ²⁴	2004	131	89	0.8	8.4	12
Eggebrecht ¹⁰	2006	609	98	0.8	11.2	24
Chen ²⁷	2006	62	100	0	4.8	1
Xu ⁴⁶	2006	63	95	0	10.6	48
Schoder ²⁶	2007	28	86	3.6	10.7	36
Verhoye ²⁸	2008	16	100	0	27	36
Fattori ²¹	2008	66	100	3.4	10.6	1
Szeto ⁴⁷	2008	35	97.1	2.8	2.8	18
<i>Chronic type B dissection</i>						
Nienaber ³⁷	1999	12	100	0	0	12
Kato ³⁸	2001	15	100	0	0	24
Eggebrecht ³⁵	2005	28	100	0	13.6	12
Chen ²⁷	2006	19	100	0	11	27

incidence of late expansion and aortic rupture.²⁵ A meta-analysis of the literature from 2000 to 2004 replicated those results on patients subjected to endovascular stent-graft repair of aortic dissection in 609 patients.¹⁰ Procedural success was obtained in 98.2% of patients, with an in-hospital surgical conversion rate of 2.3% and an in-hospital mortality rate of 5.2%. Complications such as retrograde extension of the dissection into the ascending aorta were reported in 1.9% and neurological complications in 2.9% of patients. The 30-day mortality rate and in-hospital complications were documented more often in patients undergoing stent-graft treatment for acute aortic dissection as compared to patients undergoing treatment for chronic aortic dissections (9.8% vs. 3.2% and 21.7% vs. 9.1%,

respectively; $p < 0.05$). Schoder et al. reported a 30-day mortality of 10.7% in a series of 28 patients with complicated type B aortic dissection; at 1-year follow-up, the false lumen was thrombosed in 90% of the patients, and the mean difference of diameter reduction was highly significant.²⁶ Similar results were reported by Chen et al. in their series of 62 patients.²⁷ In a series of 16 patients with complicated, acute, type B aortic dissection treated with stent grafts within 48 h after presentation, Verhoye et al. reported an early mortality rate of 25%, with no late death and a 5-year survival rate of 73%.²⁸ In a single series in which the indication for stent grafting was strictly applied to those deemed unsuitable candidates for conventional open surgical repair, the 1- and 5-year survivals were 74%

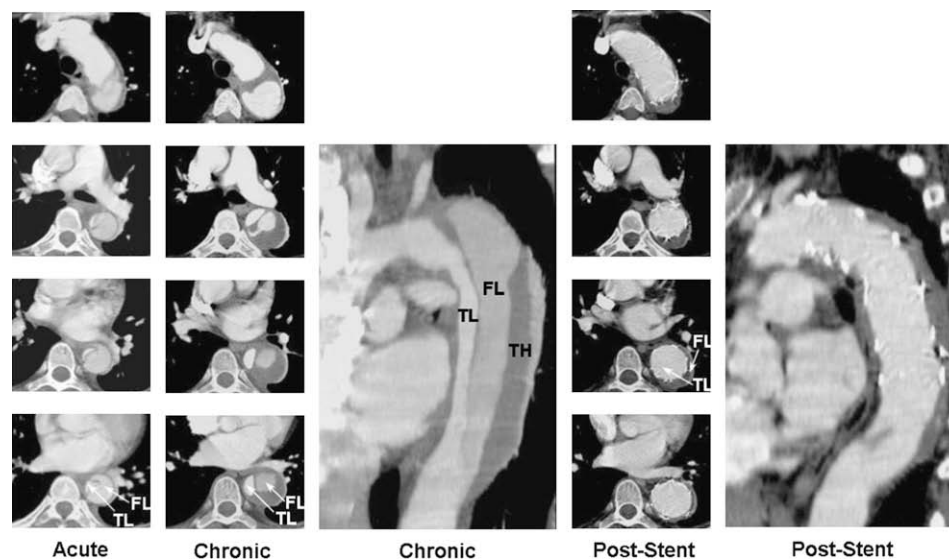


Figure 4 Type B aortic dissection in a 48-year-old man; note that there is a dynamic obstruction of the true lumen (TL) in the acute phase. In the chronic phase, there is still a partial perfusion of the false lumen with additional partial thrombosis. After stent-graft placement across the proximal thoracic entry, the entire true lumen of the thoracic aorta is reconstructed with time, with complete 'healing' of the dissected aortic wall and shrinking of the completely thrombosed false lumen (FL). TH: thrombus.

and 31%, respectively, after stent grafting compared to 93% and 78% ($p < 0.001$) survival rates, respectively, after stent grafting in patients who were reasonable candidates for conventional open repair.²⁹ Interestingly, a comparison between endovascular treatment of complicated type B aortic dissection with medical therapy of uncomplicated type B dissections in 56 patients and a follow-up of 18.1 ± 16.9 months reported similar outcomes in both groups with better mid-term fate of the descending thoracic aorta in the stent-graft group, no paraplegia and no differences in the 5-year survival rate (86.3% in both groups)³⁰ (Table 3).

Chronic Type B Aortic Dissection

The evolution of an acute dissection to a chronic dissection involves progressive thickening of the intimal flap due to fibrosis. In addition, more intimal tears are reported in chronic type B aortic dissection compared to acute dissection. The growth rate of the chronically dissected distal aorta is estimated to range from 0.1 to 0.74 cm per year depending on both the initial aortic diameter and the state of hypertension.^{31,32} Unfortunately, the long-term outcome of medical therapy alone is suboptimal, with a reported mortality rate of 50% at 5 years and delayed expansion of the false lumen in 20–50% patients at 4 years.^{1,33} This expansion of the false lumen, for which an initial diameter of more than 4 cm and a persistent perfusion of the false lumen were determined as predictors, predisposes patients to aortic rupture or retrograde migration of the dissection towards the ascending aorta with an increased mortality rate.^{34,35} Spontaneous thrombosis of the false lumen has been identified in <4% of patients.³⁶ Endovascular treatment should be considered when the aortic diameter exceeds 55–60 mm, when permanent thoracic pain occurs or in case of uncontrolled blood pressure and rapid growth of the dissecting aneurysm (>1 cm per year) (Fig. 4). Nienaber et al. prospectively evaluated stent-graft management in 12 patients with chronic type B dissection and compared the results with 12 matched surgical controls. Proximal entry closure and complete thrombosis of the false lumen at 3 months were achieved in all the patients. Stent-graft treatment resulted in no morbidity or mortality, whereas surgical treatment resulted in four deaths (33%; $p = 0.04$) and five adverse events (42%; $p = 0.04$).³⁷ Similar results were obtained by

Kato in a series of 15 patients with no mortality during a follow-up of 2 years.³⁸ Eggebrecht et al. compared the clinical outcome of 38 patients with type B aortic dissection (10 acute and 28 chronic) after endovascular stent-graft treatment. They observed significantly lower in-hospital mortality and a trend towards better 4-year survival rate in patients with underlying chronic aortic dissection³⁹ (Table 3). Whether a prophylactic implantation of stent graft in patients with chronic type B aortic dissections is superior to medical treatment alone is actually under long-term follow-up evaluation in the prospective, randomised, controlled INSTEAD trial.³⁴ At 12 months, Kaplan–Meier life-table analysis showed no mortality advantage of prophylactic stent-graft placement. The 2-year results are expected to be published.^{3,4}

Timing of Endovascular Repair

The optimal timing for endovascular intervention in type B dissections remains controversial. In 2002, Bortone et al. defended an immediate intervention within 2 weeks of the initial diagnosis; a stent-graft placement was successful in all the patients referred for intervention within the first 2 weeks.⁴⁰ Conversely, others have obtained higher mortality rates in patients with acute type B aortic dissection compared to patients with chronic aortic dissections.³⁹ Kato et al. speculated that morphological changes of the initially fragile dissecting membrane to a more fibrotic and seemingly stable membrane in the chronic phase are critical for endovascular repair and recommend a treatment after a minimum period of 4 weeks after the onset of aortic dissection.⁴¹ In addition, the more stable clinical status of the patients in the chronic phase of aortic dissection may be an important determinant of better survival following endovascular repair. On the other hand, patients with acute aortic dissection have the greater potential for stent-graft-induced complete remodelling of the entire aorta (Fig. 5). Shimono et al. reported that complete obliteration and resolution of the false lumen following endovascular stent-graft treatment were more frequently achieved in patients with acute aortic dissection compared to patients with chronic aortic dissection (70% vs. 38.5%).⁴² In fact, due to lack of prospective randomised data comparing immediate and delayed intervention in various clinical and anatomical constellations, no general recommendation has been issued with respect to timing of endovascular treatment so far; observational evidence, however, may favour an early intervention, when justified by complications.

Long-Term Follow-Up and Adjunctive Treatment

The long-term approach to patients with successful initial treatment of aortic dissection begins with an appreciation that such patients have a systemic illness that invariably involves the entire aorta and branches as targets for future complications. Systemic hypertension, advanced age, aortic size and presence of patent false lumen are all factors that identify higher risk.^{33,43} Therefore, all patients deserve aggressive medical therapy, follow-up visits and surveillance, including serial imaging. Treatment with

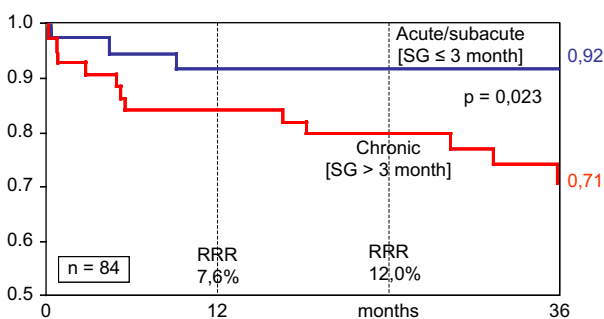


Figure 5 Impact of treatment timing on event (MAVE) free survival in patients with acute aortic dissection (own results).

effective beta-blocking agents, and potentially sartans, is the cornerstone of medical therapy regardless of whether their in-hospital definitive treatment was surgical, medical or interventional. Pure vasodilators, such as dihydropyridine calcium-channel antagonists or hydralazin, may cause an increase in dP/dt and should therefore be used only in conjunction with adequate beta-blockade. ACE inhibitors are attractive antihypertensive agents for treating aortic dissection and may be of particular benefit in patients with some degree of renal ischaemia as a consequence of the dissection. Late aneurysm rupture after aortic dissection is 10 times more common in patients with poorly controlled hypertension than in those with controlled blood pressure.³³ The guidelines recommend progressive up-titration of dosage to achieve a blood pressure <135/80 mm Hg.^{1,2,44} Serial imaging for the aorta is an essential component of long-term treatment and follow-up of patients with aortic aneurysm (before and after surgery or stent-graft placement) in all cases of chronic dissection. Choice of imaging modality may vary with institutional availability and expertise, and also with the extent of aortic involvement and age of the patient. Previous recommendations suggest follow-up imaging and examination at 1, 3, 6, 9 and 12 months after discharge and annually thereafter.^{1,2} This aggressive strategy supports the notion that both hypertension and aortic expansion/dissection are common and not easily predicted in the first months after hospital discharge. Furthermore, imaging is not confined simply to the region of initial involvement because both dissection and aneurysm formation may occur anywhere along the entire length of the aorta. The patients who have been treated by open surgery and/or endovascular stent grafting warrant similar a follow-up than those whose initial strategy was limited to medical treatment alone.

Conflict of Interest/Funding

None.

References

- Hagan PG, Nienaber CA, Isselbacher EM, Bruckman D, Karavite DJ, Russman PL, et al. The international registry of acute aortic dissection (IRAD). *JAMA* 2000;**283**:897–903.
- Erbel R, Alfonso F, Boileeau C, Dirsch O, Eber B, Haverich A, et al. Diagnosis and management of aortic dissection. *Eur Heart J* 2001;**22**:1642–81.
- Clouse WD, Hatlett JW, Schaff HV, Spittell PC, Rowland CM, Ilstrup DM, et al. Acute aortic dissection: population-based incidence compared with degenerative aortic aneurysm rupture. *Mayo Clin Proc* 2004;**79**(2):176–80.
- Kodolitsch Y, Schwartz AG, Nienaber CA. Clinical prediction of acute aortic dissection. *Arch Intern Med* 2000;**160**:2977–82.
- Estrera AL, Miller CC, Safi H, Goodrick JS, Keyhani A, Porat EE, et al. Outcomes of medical management of acute type B aortic dissection. *Circulation* 2006;**114**(Suppl. 1):384–9.
- Nienaber CA, Fattori R, Mehta RH, Richartz BM, Evangelista A, Petzsch M, et al. Gender-related differences in acute aortic dissection. *Circulation* 2004;**109**:3014–21.
- Suzuki T, Mehta RH, Ince H, Nagai R, Sakamura Y, Weber F, et al. Clinical profiles and outcomes of acute type B aortic dissection in the current era: lessons from the International Registry of Aortic Dissection (IRAD). *Circulation* 2003;**108**(Suppl. II):II312–7.
- Beregi JP, Haulon S, Otal P, Thony F, Bartoli JM, Crochet D, et al. Endovascular treatment of acute complications associated with aortic dissection: midterm results from a multicenter study. *J Endovasc Ther* 2003;**10**:486–93.
- Nienaber CA, Ince H, Weber F, Rehders T, Petzsch M, Meinertz T, et al. Emergency stent-graft placement in thoracic aortic dissection and evolving rupture. *J Card Surg* 2003;**18**:464–70.
- Eggebrecht H, Nienaber CA, Neuhäuser M, Baumgart D, Kische S, Schmermund A, et al. Endovascular stent-graft placement in aortic dissection: a meta-analysis. *Eur Heart J* 2006;**27**:489–98.
- Kodama K, Nishigami K, Sakamoto T, Sawamura T, Hirayama T, Mirsumi H, et al. Tight heart rate control reduces secondary adverse events in patients with type B acute aortic dissection. *Circulation* 2008;**118**(Suppl. 1):S167–70.
- Tsai TT, Fattori R, Trimarchi S, Isselbacher E, Myrmel T, Evangelista A, et al. Long-term survival in patients with type B acute aortic dissection: insight from the International Registry of Acute Aortic Dissection. *Circulation* 2006;**114**:2226–31.
- Tsai TT, Evangelista A, Nienaber CA, Myrmel T, Meinhardt G, Cooper JV, et al. Partial thrombosis of the false lumen in patients with acute type B aortic dissection. *N Engl J Med* 2007;**357**:349–59.
- Svensson LG, Crawford ES, Hess KR, Coselli JS, Safi HJ. Variables predictive of outcome in 832 patients undergoing repairs of the descending thoracic aorta. *Chest* 1993;**104**(4):1248–53.
- von Segesser LK, Killer I, Ziswiler M, Linka A, Ritter M, Jenni R, et al. Dissection of the descending thoracic aorta extending into the ascending aorta. A therapeutic challenge. *J Thorac Cardiovasc Surg* 1994;**108**(4):755–61.
- Roberts CS, Roberts WC. Aortic dissection with the entrance tear in the descending thoracic aorta: analysis of 40 necropsy patients. *Ann Surg* 1991;**213**:356–68.
- Shaw RS. Acute dissecting aortic aneurysm. Treatment by fenestration of the internal wall of the aneurysm. *N Engl J Med* 1995;**253**:331–3.
- Eleftriades JA, Hammond GL, Gusberg RJ, Kopf GS, Baldwin JC. Fenestration revisited. A safe and effective procedure for descending aortic dissection. *Arch Surg* 1990;**125**:786–90.
- Miller DC, Mitchell RS, Oyer PS, Stinson EB, Jamieson SW, Shumway NE. Independent determinants of operative mortality for patients with aortic dissection. *Circulation* 1984;**70**(Suppl. 1):1153–64.
- Trimarchi S, Nienaber CA, Rampoldi V, Myrmel T, Suzuki T, Bossone E, et al. Role and results of surgery in acute type B aortic dissection: insights from the International Registry of Acute Aortic Dissection (IRAD). *Circulation* 2006;**114**(1 Suppl):I357–64.
- Fattori R, Tsai TT, Myrmel T, Evangelista A, Cooper JV, Trimarchi S, et al. Complicated acute type B dissection: is surgery still the best option? *J Am Coll Cardiol Intv* 2008;**1**:395–402.
- Fattori R, Lovato L, Buttazzi K, Ruzzo V. Evolving experience of percutaneous management of type B aortic dissection. *Eur J Vasc Endovasc Surg* 2006;**31**:115–22.
- Nienaber CA, Kische S, Zeller T, Rehders TC, Schneider H, Lorenzen B, et al. Provisional extension to induce complete attachment after stent-graft placement in type B aortic dissection: the PETICOAT concept. *J Endovasc Ther* 2006;**13**:738–46.
- Leurs L, Bell R, Degrieck Y, Thomas S, Hober R, Lundbom J, et al. Endovascular treatment of thoracic aortic diseases: combined experience from the EUROSTAR and United Kingdom Thoracic Endograft registries. *J Vasc Surg* 2004;**40**:670–9 [discussion: 679–8].
- Nathanson DR, Rodriguez-Lopez JA, Ramaiah VG, Williams J, Olsen DM, Wheatley GH, et al. Endoluminal stent-graft

- stabilization for thoracic aortic dissection. *J Endovasc Ther*; 2005;354–9.
- 26 Schoder M, Czerny M, Cejna M, Rand T, Stadler A, Sodeck GH, et al. Endovascular repair of acute type B aortic dissection: long-term follow-up of true and false lumen diameter change. *Ann Thorac Surg* 2007;83:1059–66.
- 27 Chen S, Yei F, Zhou L, Zhang J, Shan S, Tian N, et al. Endovascular stent-grafts treatment in acute aortic dissection (type B): clinical outcomes during early, late or chronic phases. *Catheter Cardiovasc Interv* 2006;68:319–25.
- 28 Verhoye JP, Miller DC, Sze D, Dake MD, Mitchell RS. Complicated acute type B aortic dissection: midterm results of emergency endovascular stent-grafting. *J Thorac Cardiovasc Surg* 2008;136:424–30.
- 29 Demers P, Miller DC, Mitchell RS, Kee ST, Sze D, Razavi MK, et al. Midterm results of endovascular repair of descending thoracic aortic aneurysms with first-generation stent-grafts. *J Thorac Cardiovasc Surg* 2004;127:664–73.
- 30 Dialeto G, Cocino FE, Scognamiglio G, Manduca S, Della Corte A, Giannolo B, et al. Treatment of type B aortic dissection: endoluminal repair or conventional medical therapy? *Eur J Cardiothorac Surg* 2005;27:826–30.
- 31 Doroghazi RM, Slater EE, DeSanctis RW, Buckley MJ, Austen WG, Rostenthal S. Long-term survival of patients with treated aortic dissection. *J Am Coll Cardiol* 1984;3:1026–34.
- 32 Hata M, Shiono M, Inoue T, Sezai A, Niino T, Negishi N, et al. Optimal treatment of type B acute aortic dissection: long-term follow-up results. *Ann Thorac Surg* 2003;75:1781–4.
- 33 Neya K, Omoto R, Kyo S, Kimura S, Yokote Y, Takamoto S, et al. Outcome of Stanford type B acute aortic dissection. *Circulation* 1992;86(Suppl. II):II1–7.
- 34 Nienaber CA, Zannetti S, Barbieri B, Kische S, Schareck W, Rehders TC. Investigation of Stent grafts in patients with type B Aortic Dissection Design of the INSTEAD trial – a prospective, multicenter, European randomized trial. *Am Heart J* 2005;149:592–9.
- 35 Kato M, Bai H, Sato K, Kawamoto S, Kaneko M, Ueda T, et al. Determining surgical indications for acute type B dissection based on enlargement of aortic diameter during the chronic phase. *Circulation* 1995;92(Suppl.):II107–12.
- 36 Erbel R, Oelert H, Meyer J, Puth M, Mohr-Katoly S, Hausmann D, et al. Effect of medical and surgical therapy on aortic dissection evaluated by transesophageal echocardiography. Implications for prognosis and therapy. The European Cooperative Study on Echocardiography. *Circulation* 1993;87:1604–15.
- 37 Nienaber CA, Fattori R, Lund G, Dieckmann C, Wolf W, von Kodolitsch Y, et al. Nonsurgical reconstruction of thoracic aortic dissection by stent-graft placement. *N Engl J Med* 1999;340:1539–45.
- 38 Kato N, Hirano T, Shimono T, Ishida M, Takano K, Nishide Y, et al. Treatment of chronic aortic dissection by transluminal endovascular stent-graft placement: preliminary results. *J Vasc Interv Radiol* 2001;12:835–40.
- 39 Eggebrecht H, Herold U, Kuhnt O, Schmermund A, Bartel T, Martini S, et al. Endovascular stent-graft treatment of aortic dissection: determinants of post-interventional outcome. *Eur Heart J* 2005;26:489–97.
- 40 Bortone AS, Schena S, D'Agostino D, Dialeto G, Paradiso V, Mannatrazio G, et al. Immediate versus delayed endovascular treatment of post-traumatic aortic pseudoaneurysms and type B dissections: retrospective analysis and premises to the upcoming European trial. *Circulation* 2002;106:234–40.
- 41 Kato N, Hirano T, Ishida M, Shimono T, Cheng SH, Yada I, et al. Acute and contained rupture of the descending thoracic aorta: treatment with endovascular stent-grafts. *J Vasc Surg* 2003;37:100–5.
- 42 Shimono T, Kato N, Yasuda F, Suzuki T, Yuasa U, Ouda K, et al. Transluminal stent-graft placements for the treatments of acute onset and chronic aortic dissections. *Circulation* 2002;106:1241–7.
- 43 Shores J, Berger KR, Murphy EA, Pyeritz RE. Progression of aortic dilatation and the benefit of long-term beta adrenergic blockade in Marfan's syndrome. *N Engl J Med* 1994;330:1335–41.
- 44 Glower DD, Speier RH, White WD, Smith LR, Rankin JS, Wolfe WG. Management and long-term outcome of aortic dissection. *Ann Surg* 1991;214:31–41.
- 45 Bortone AS, De Cillis E, D'Agostino D, de Luca Tuppiti Schinosa L. Treatment of thoracic aortic disease. Four years of experience. *Circulation* 2004;110(Suppl. II):II262–7.
- 46 Xu S, Huang F, Yang J, Li ZZ, Wang XY, Zhang ZG, et al. Endovascular repair of acute type B aortic dissection: early and mid-term results. *J Vasc Surg* 2006;43(6):1090–5.
- 47 Szeto WY, McGarvey M, Pochettino A, Moser GW, Hoboken A, Cornelius K, et al. Results of a new surgical paradigm: endovascular repair for acute complicated type B aortic dissection. *Ann Thorac Surg* 2008;86:87–94.
- 48 Kische S, Ehrlich MP, Nienaber CA, Rousseau H, Hejman R, Piquet P, et al. TTR registry data in all type B dissection. *ACTS*, in press.